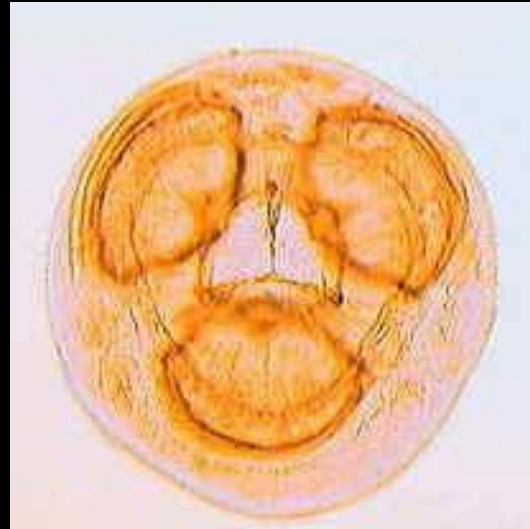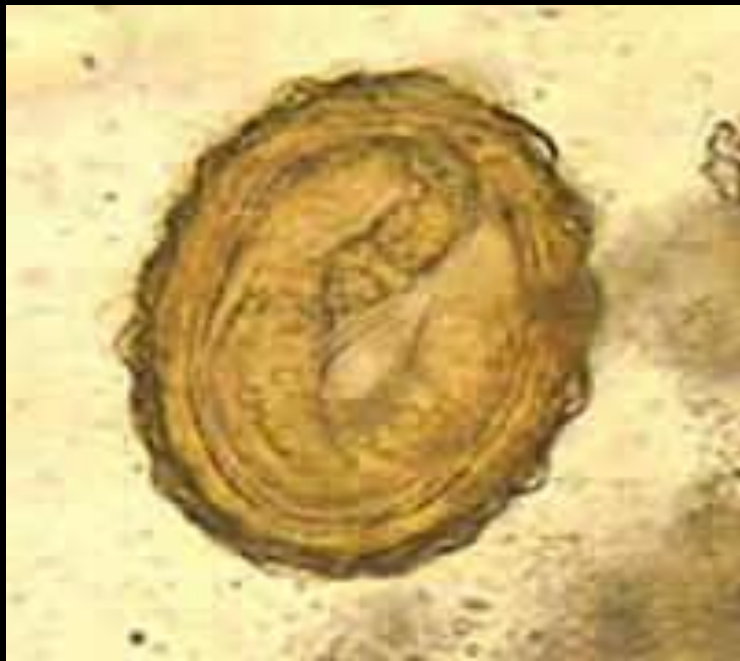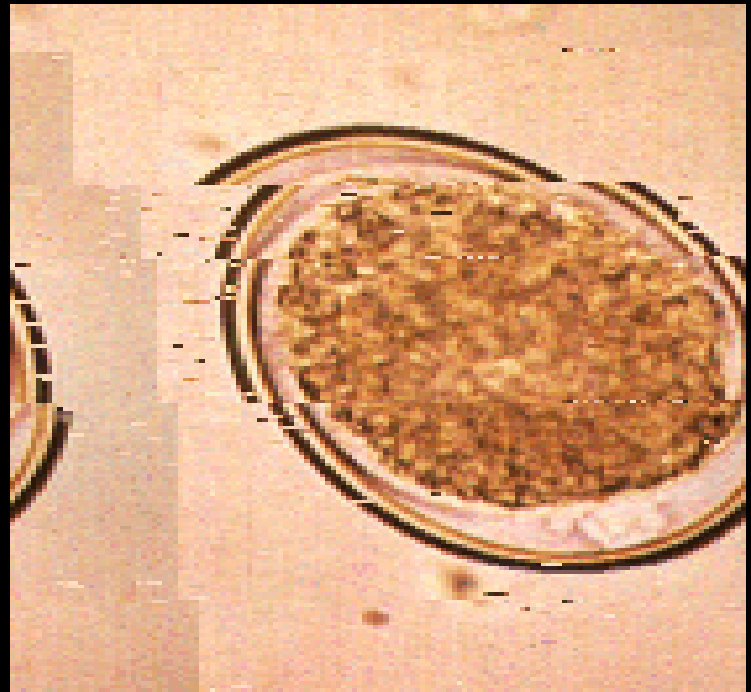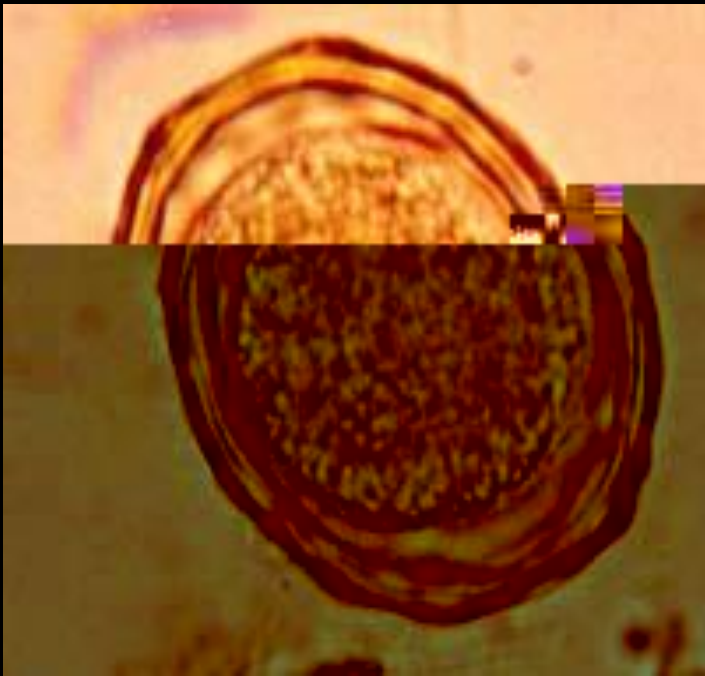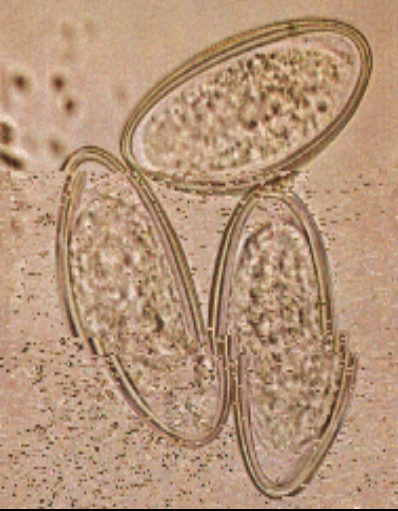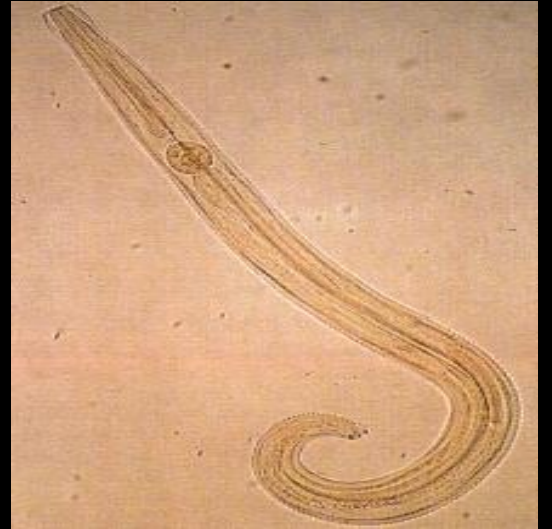



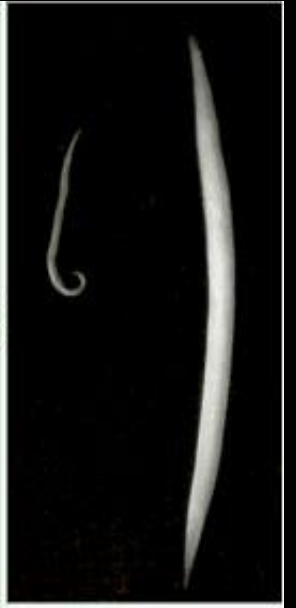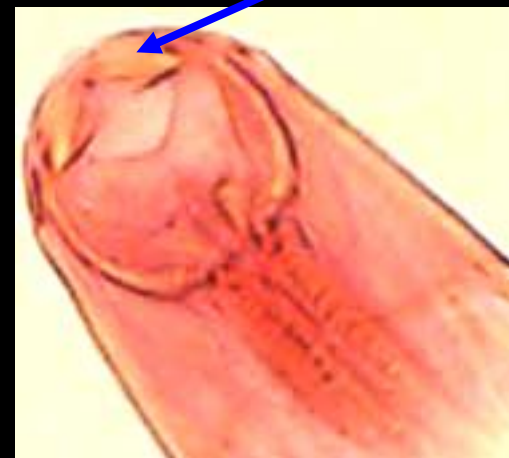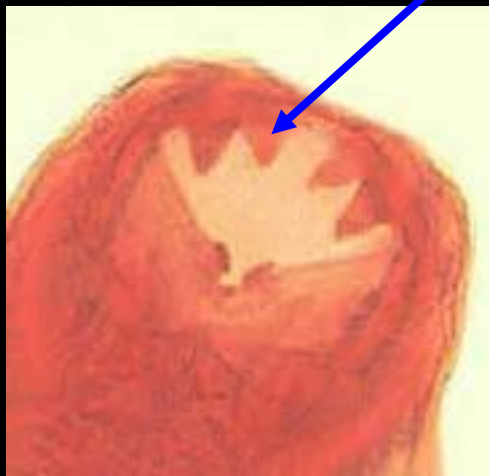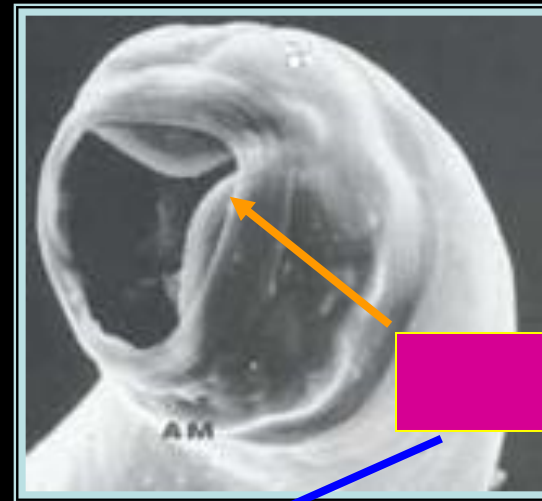
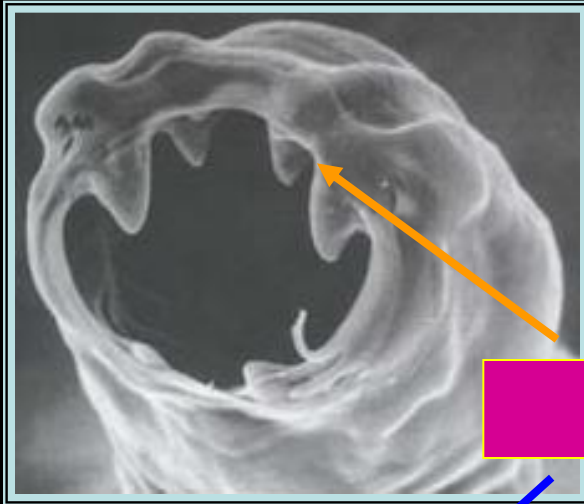



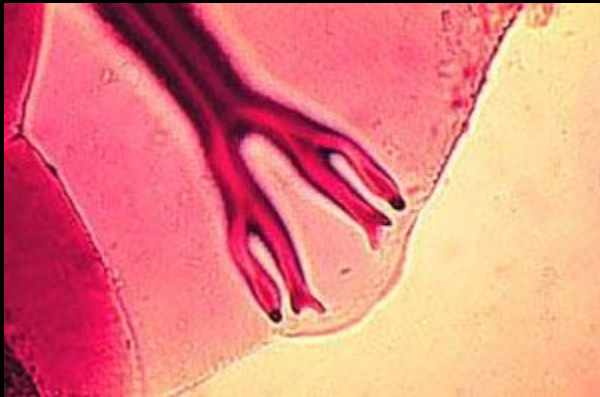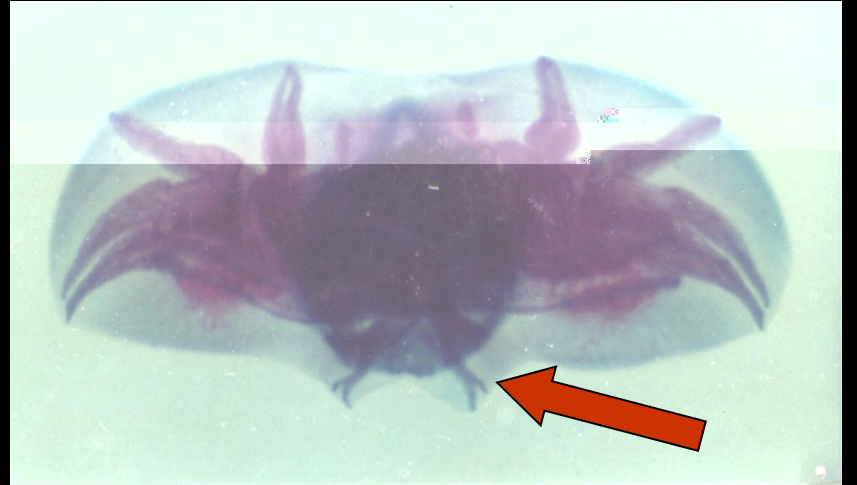



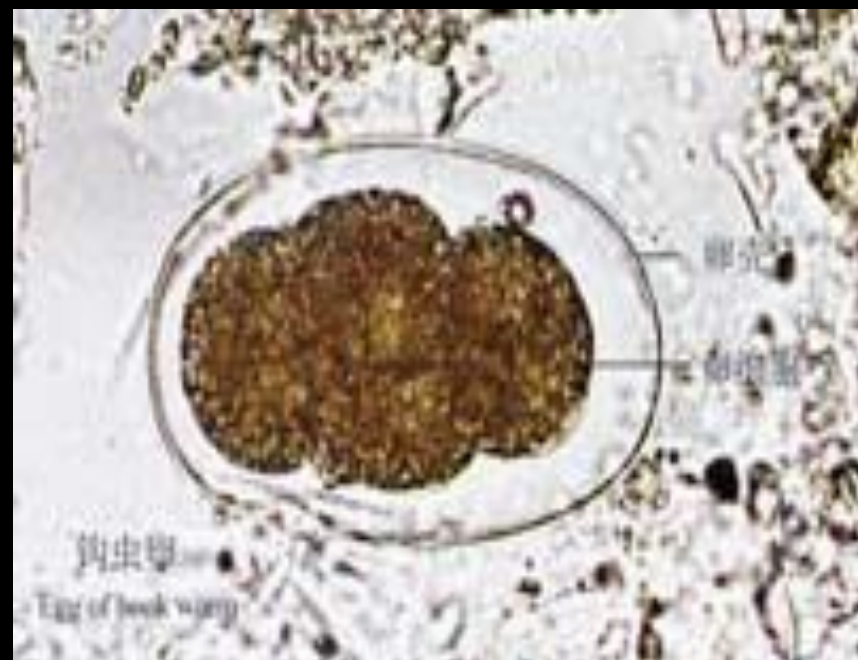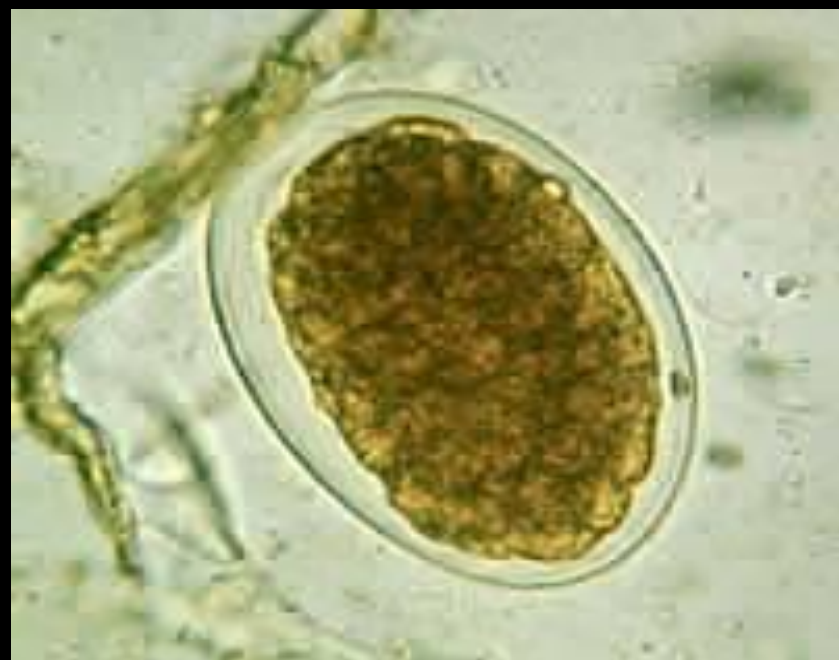雌虫



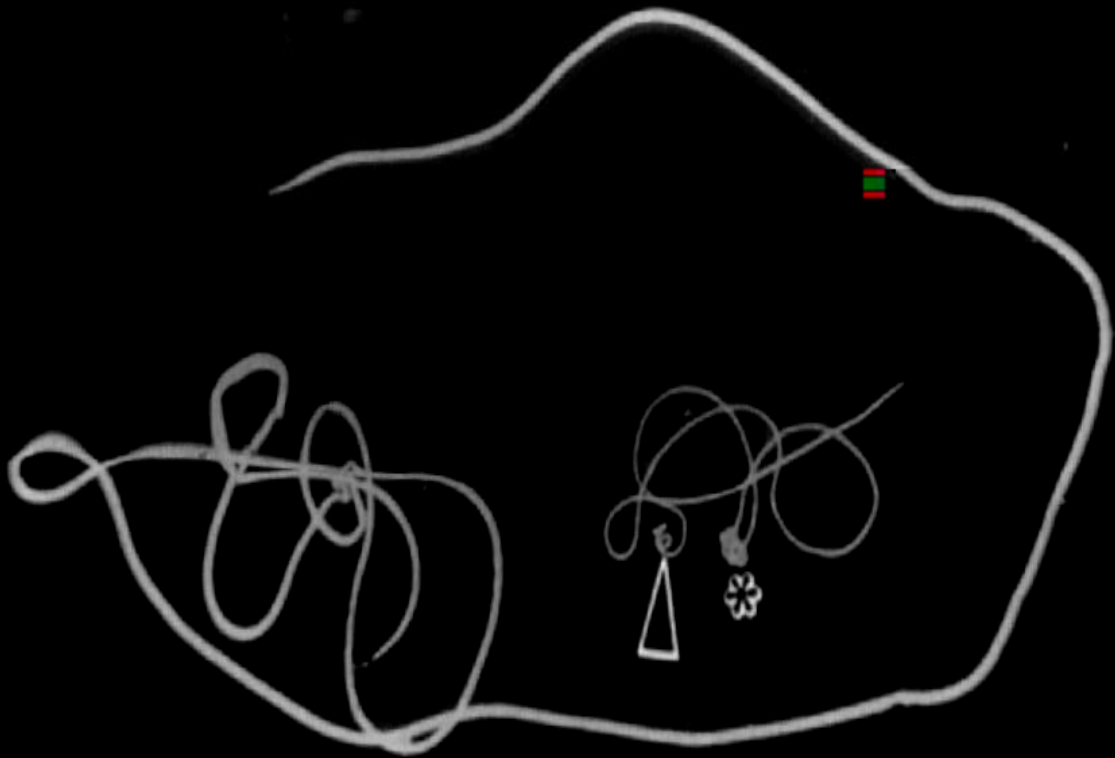


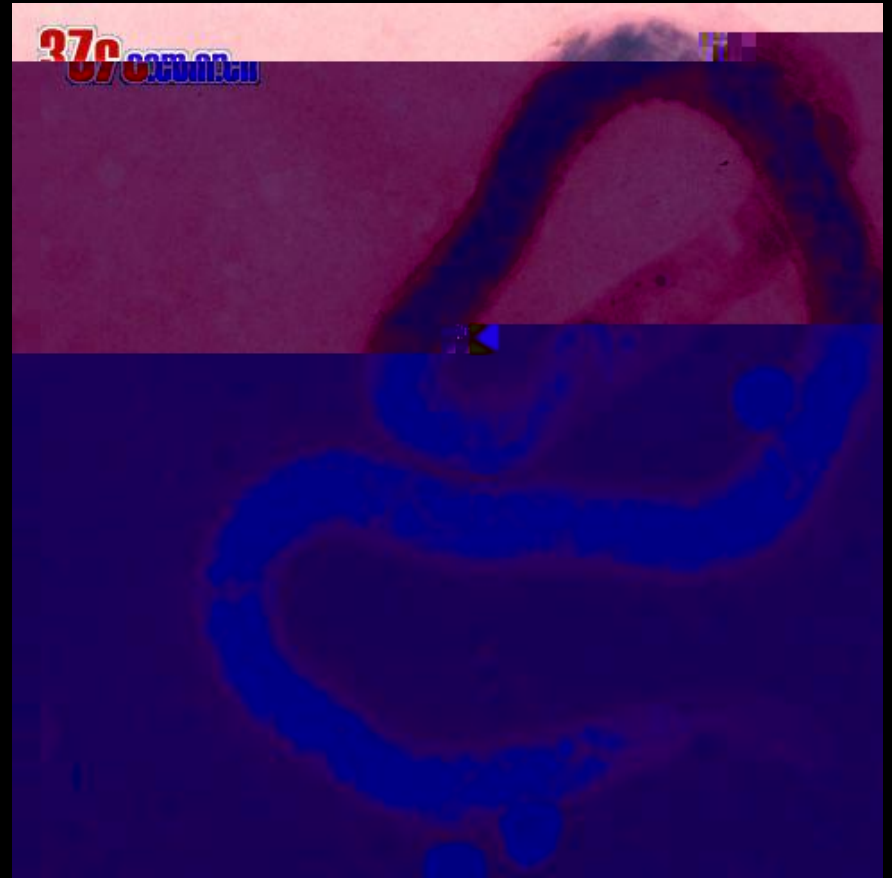
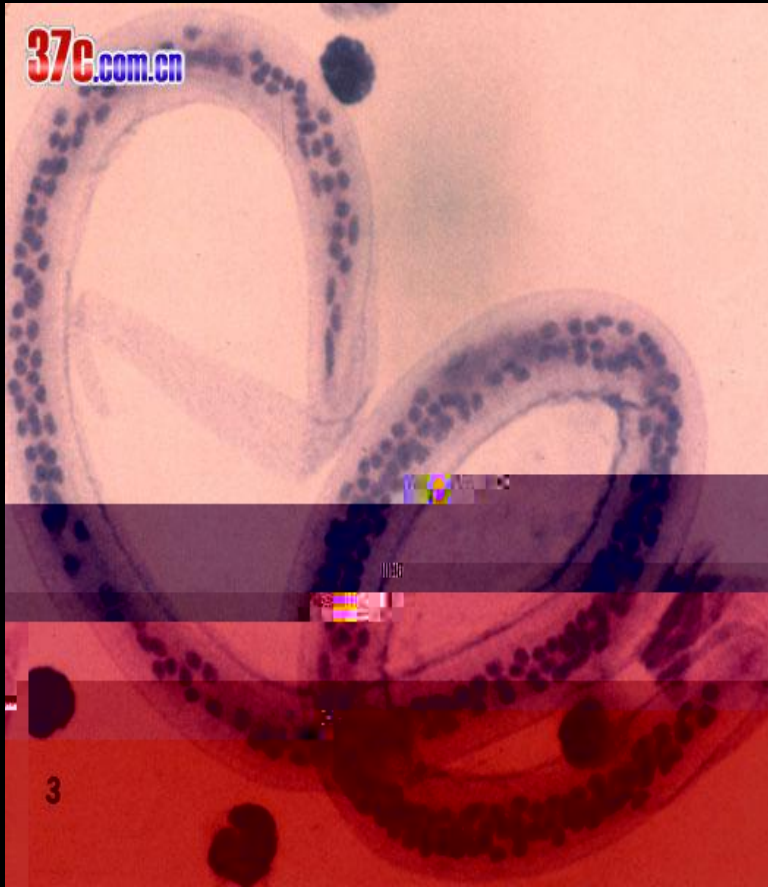




1



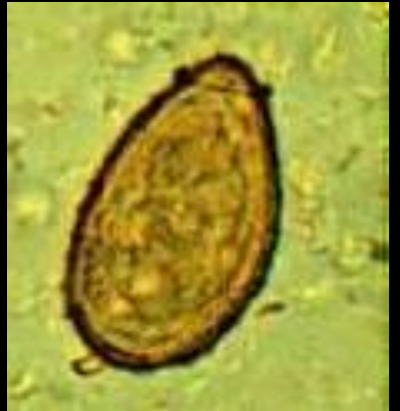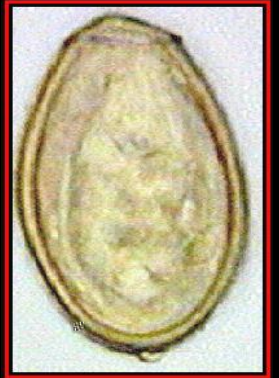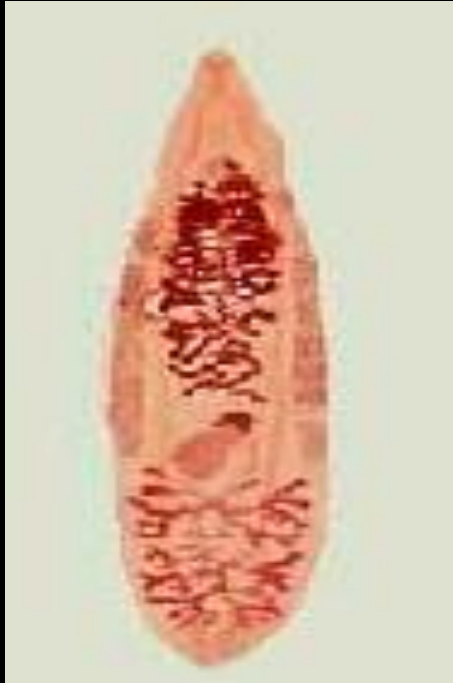


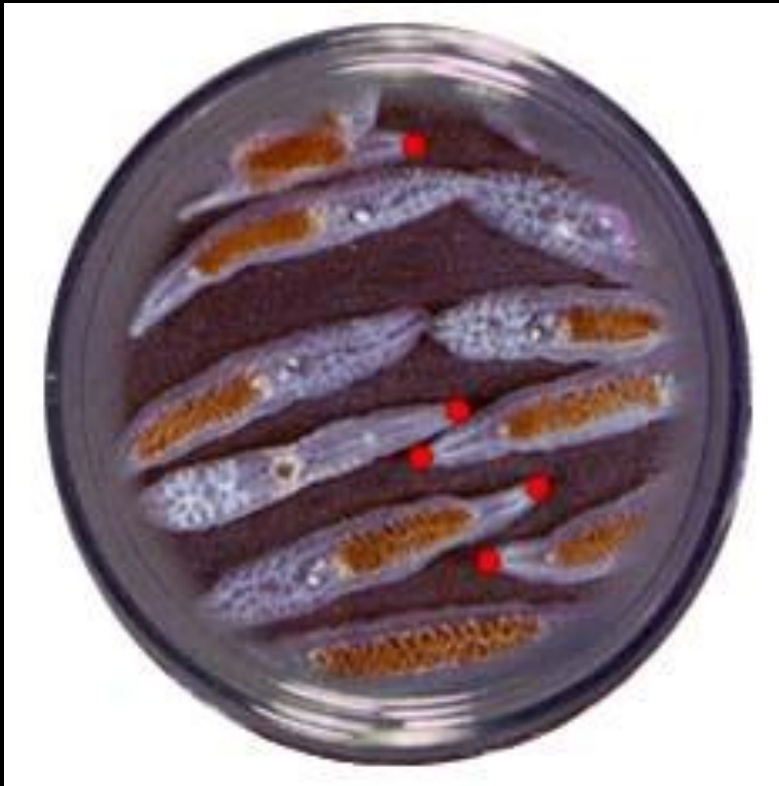

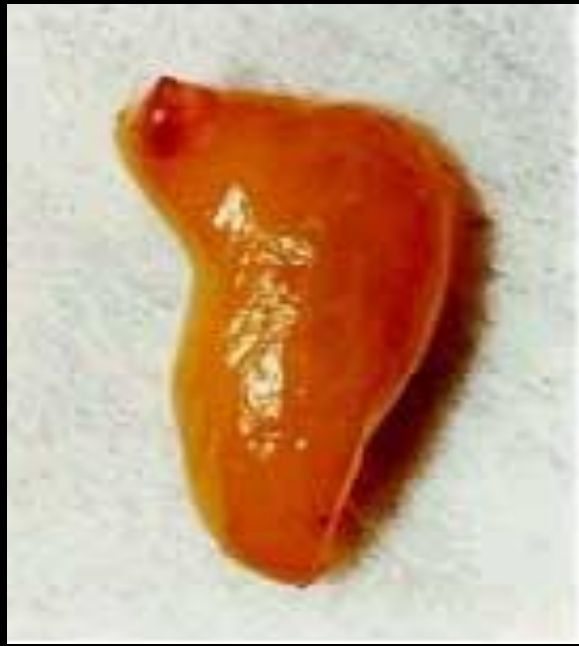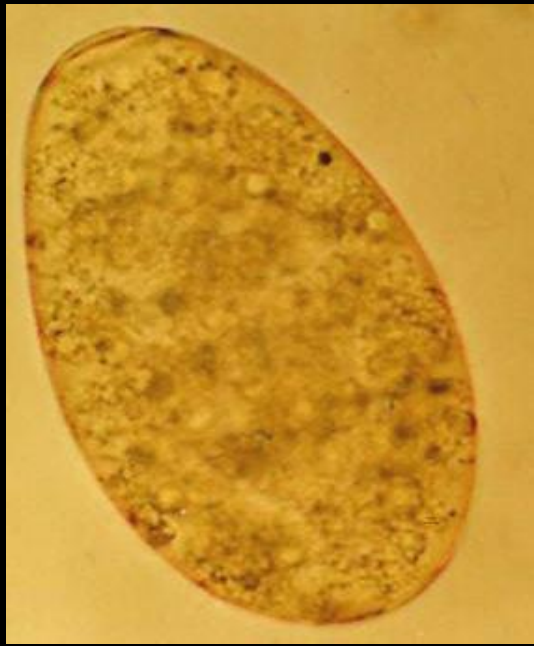1.

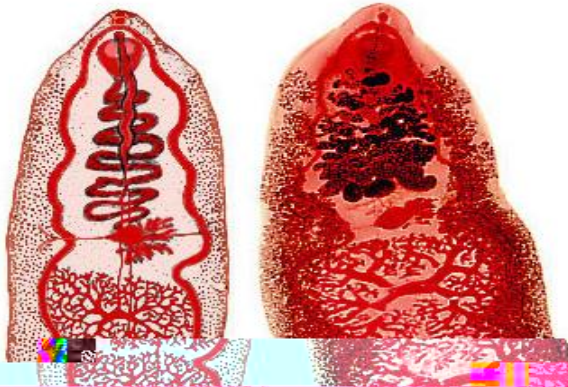2.

3.



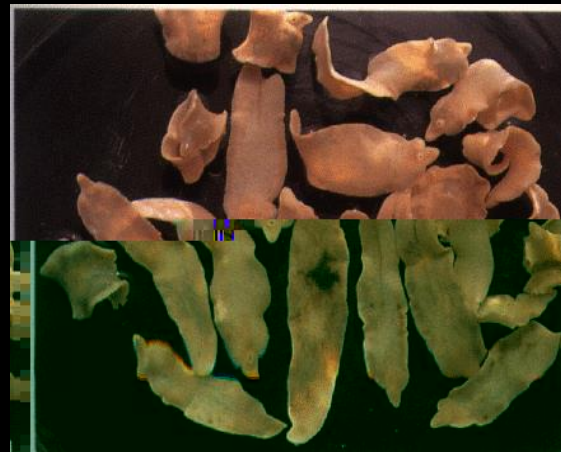

背腹扁平，
叶片状，
肥厚，
呈肉红色。

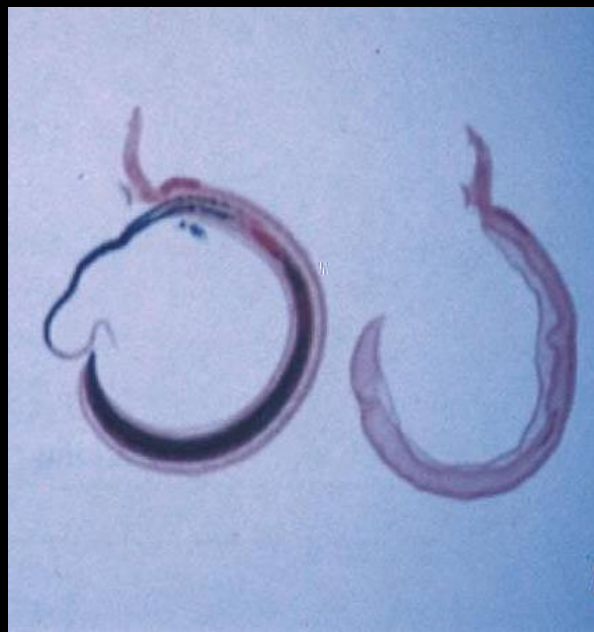
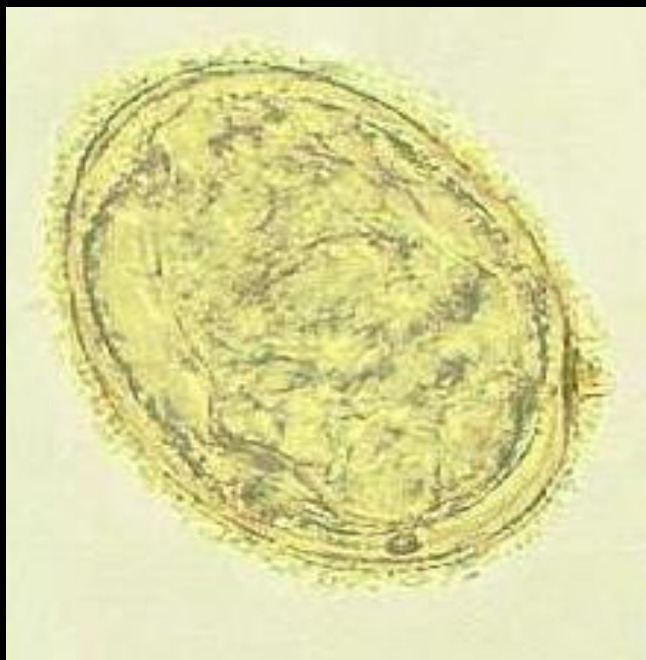

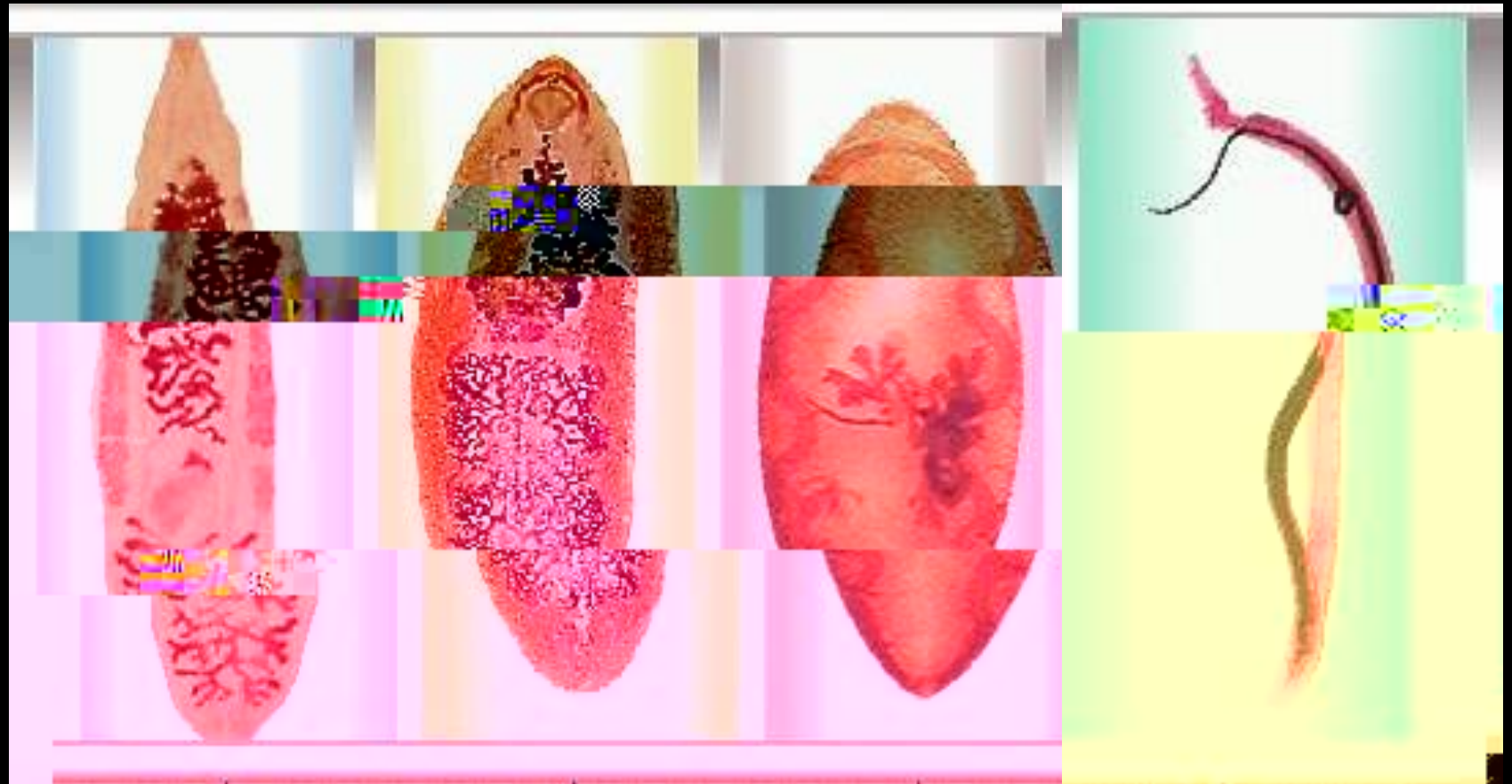
模式图

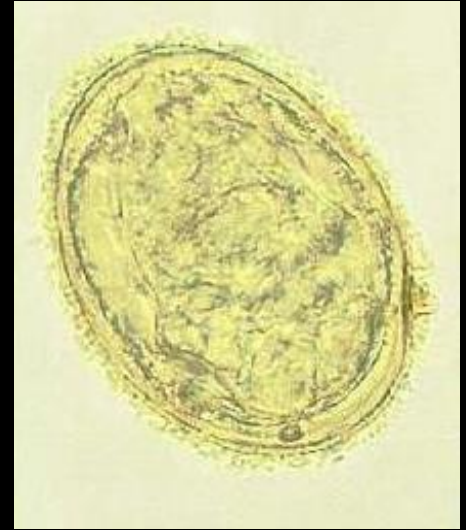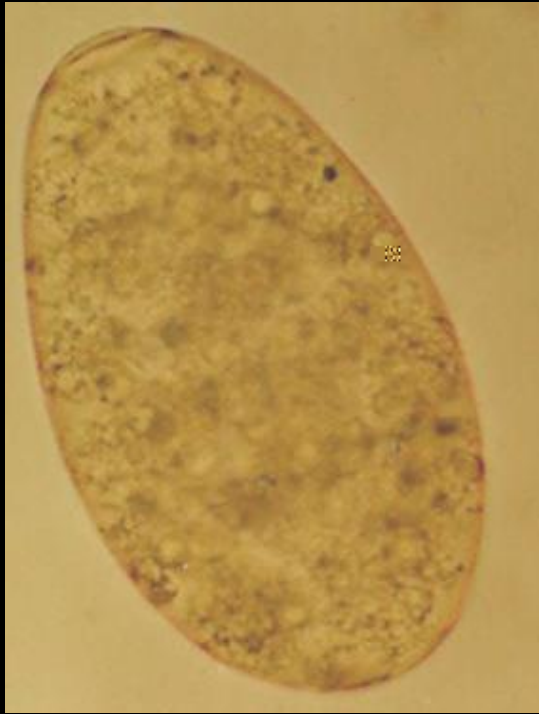
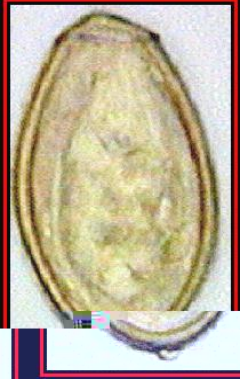染色标本



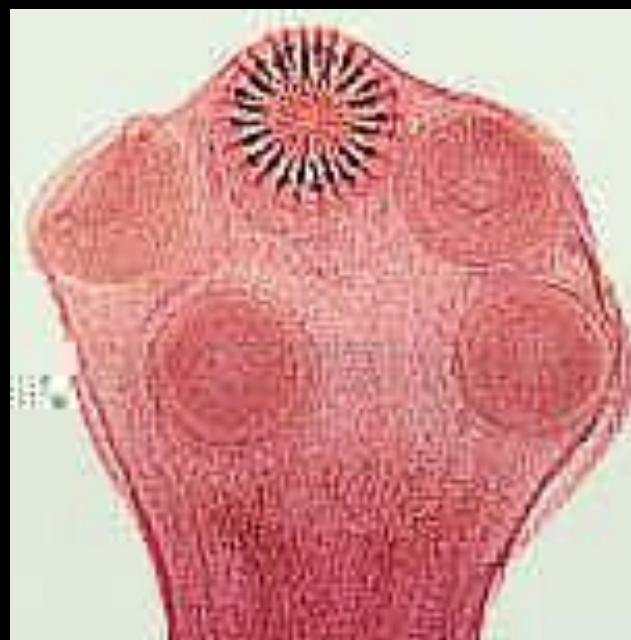
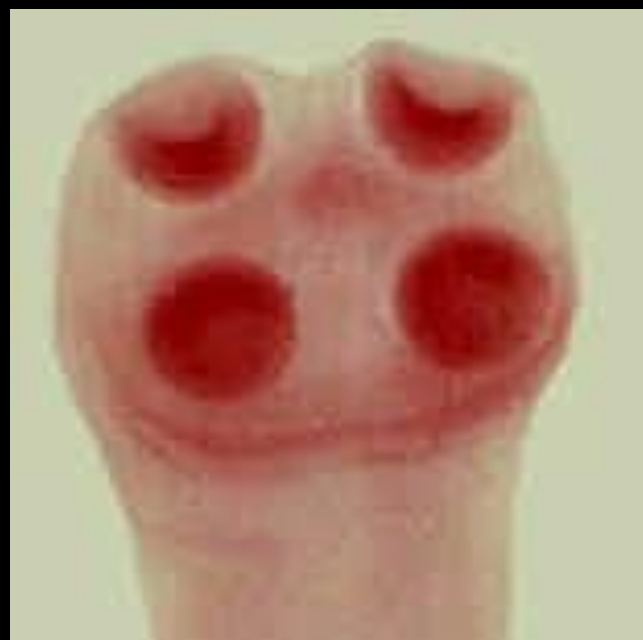







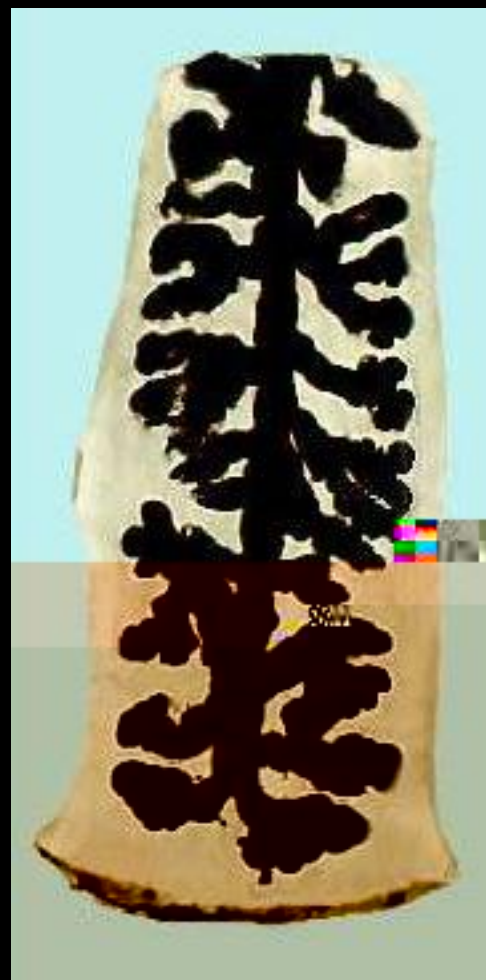
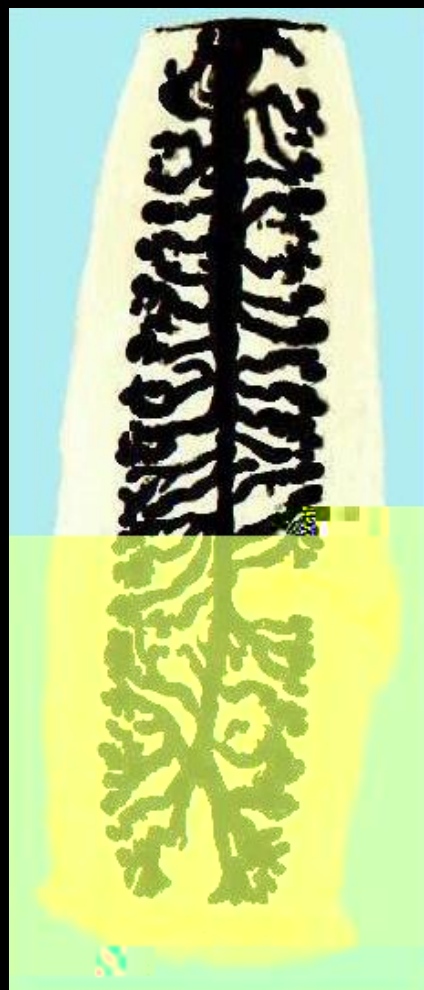





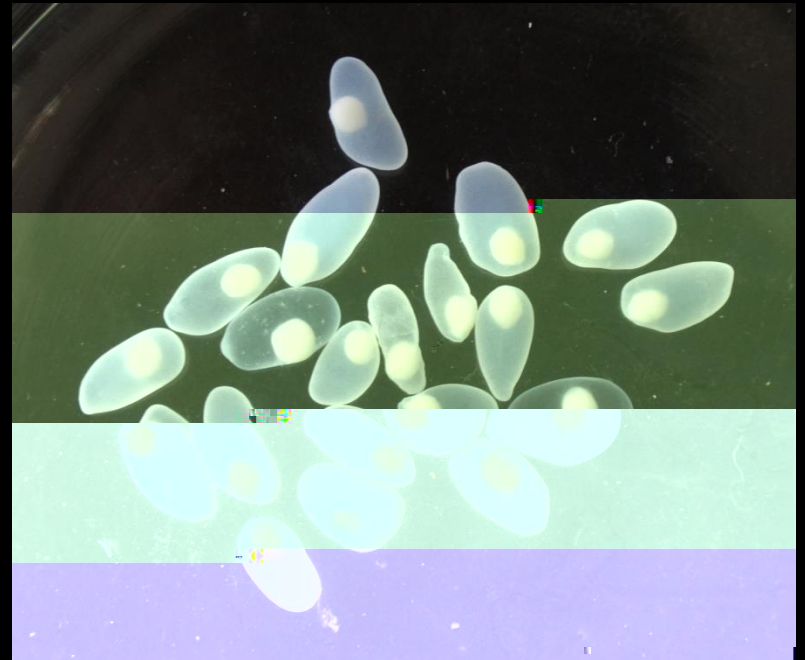
带绦虫头节

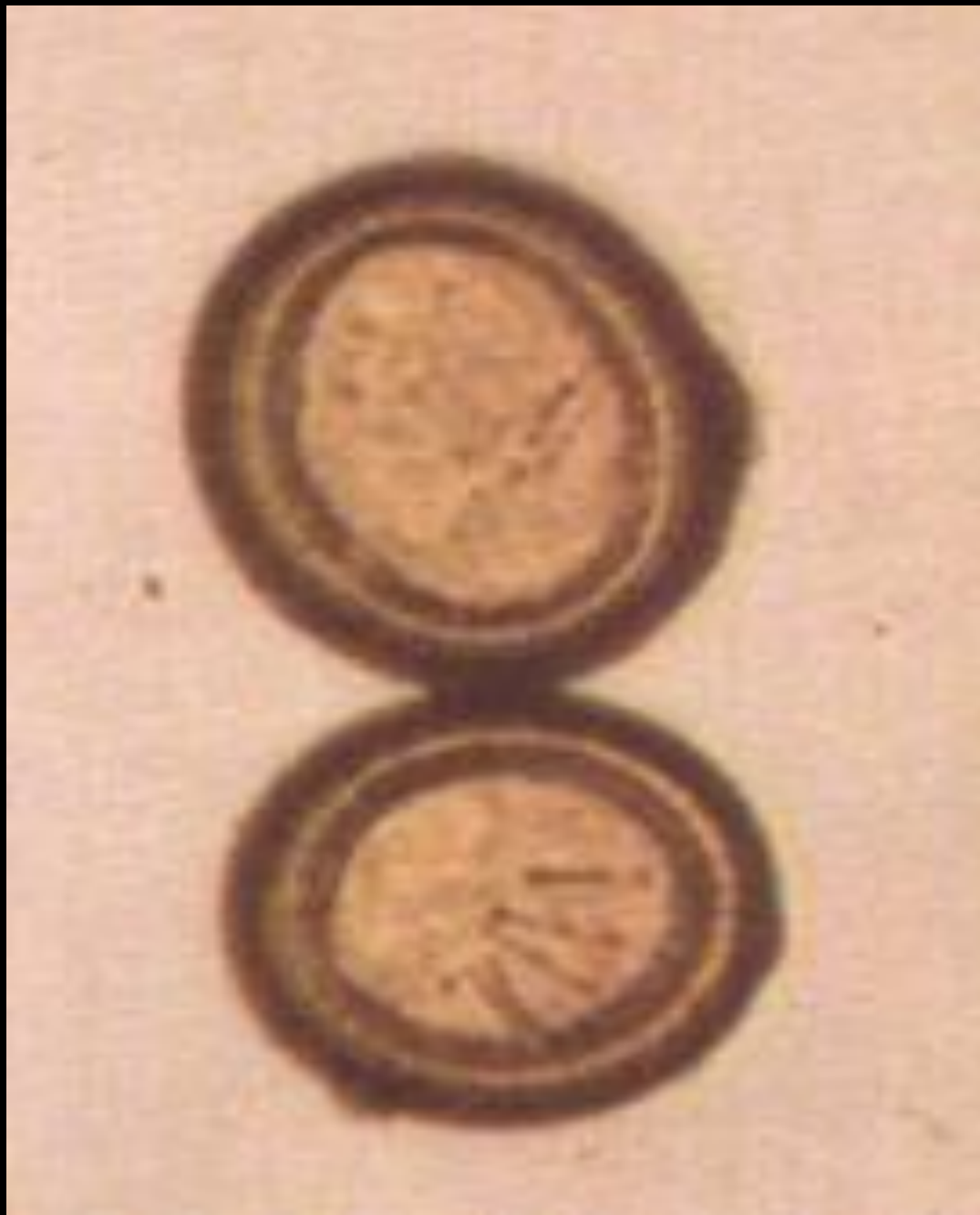

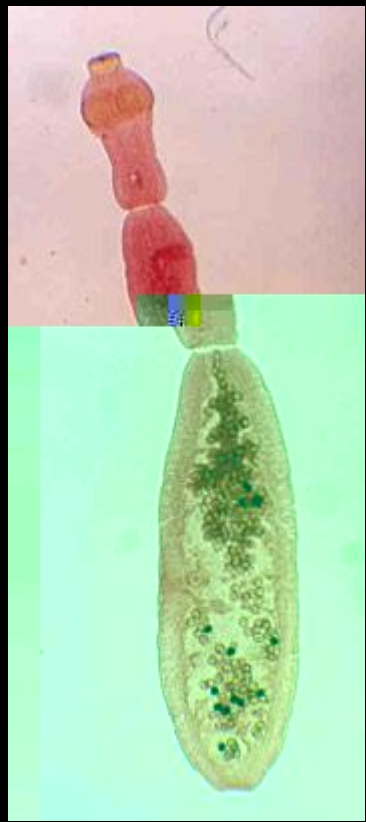
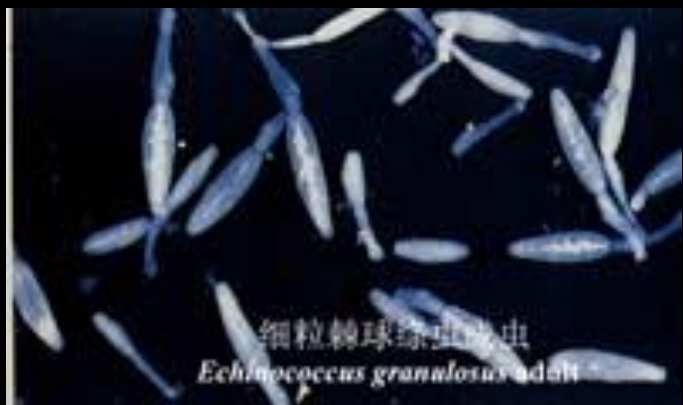带绦虫成节




带绦虫孕节

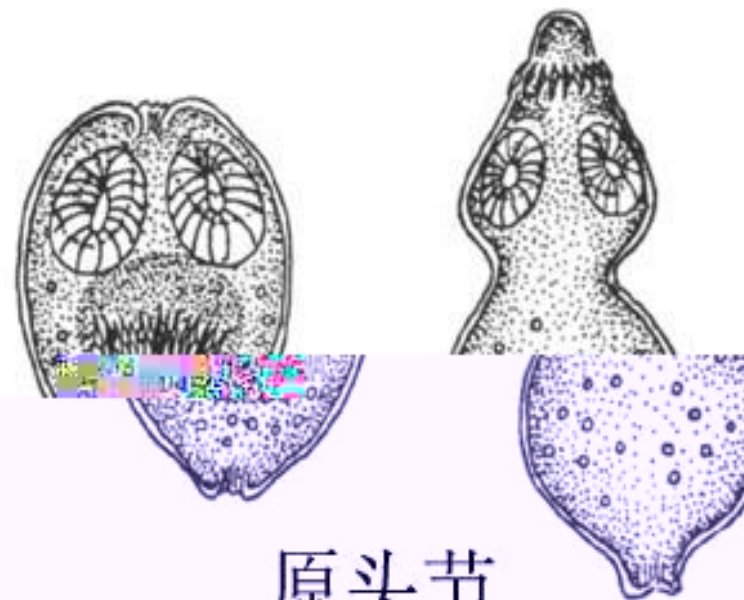
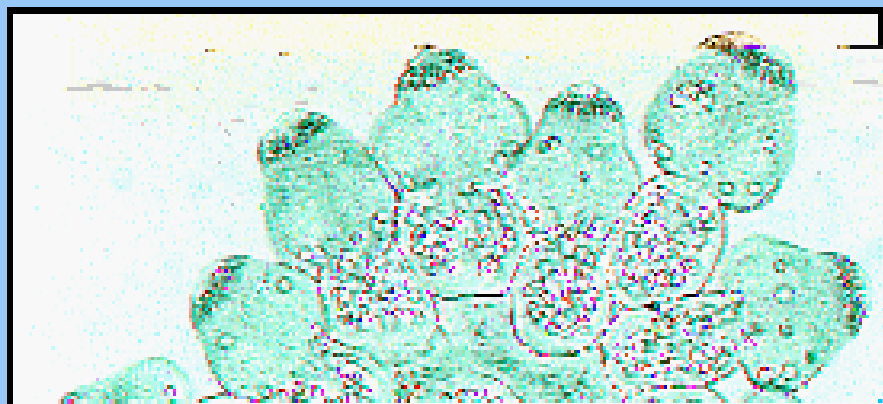






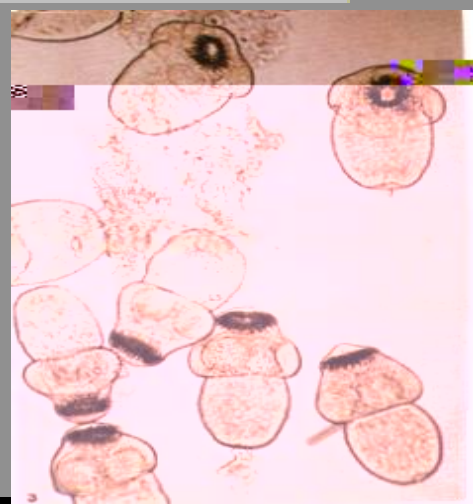



—



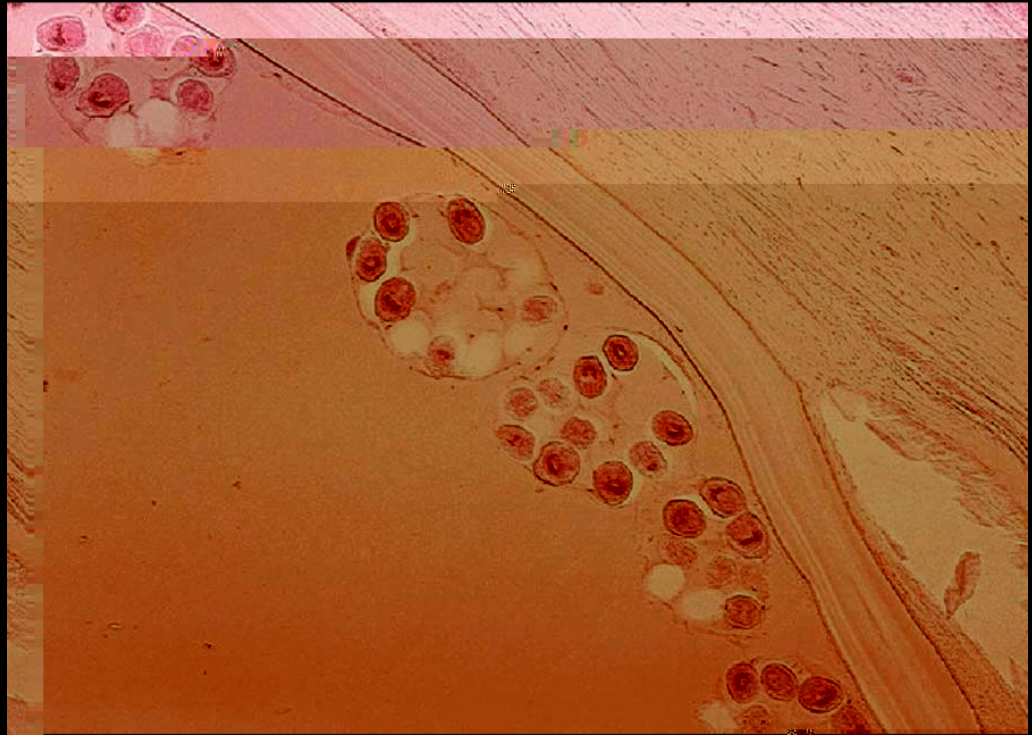
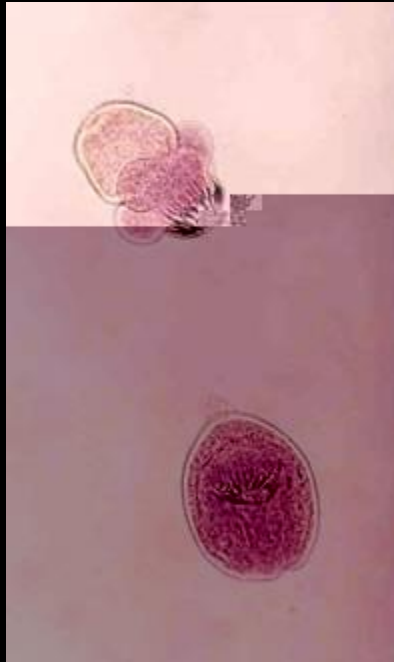
原头节

原头节




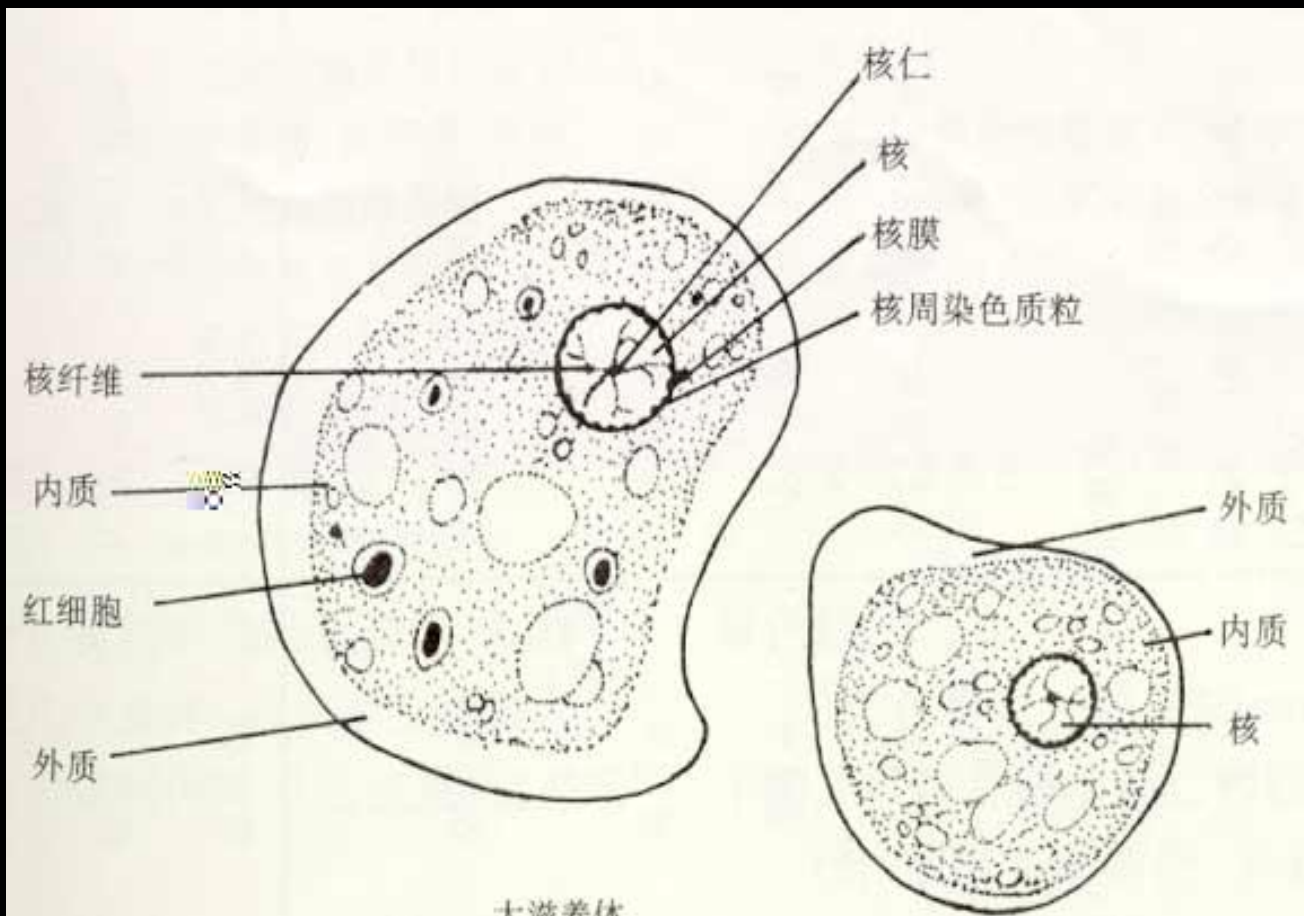
无色透明，椭圆形或圆形，为向
翻卷收缩的头节，可见内陷的顶突、
盘以及小钩。图中向内翻卷的头节
翻出。

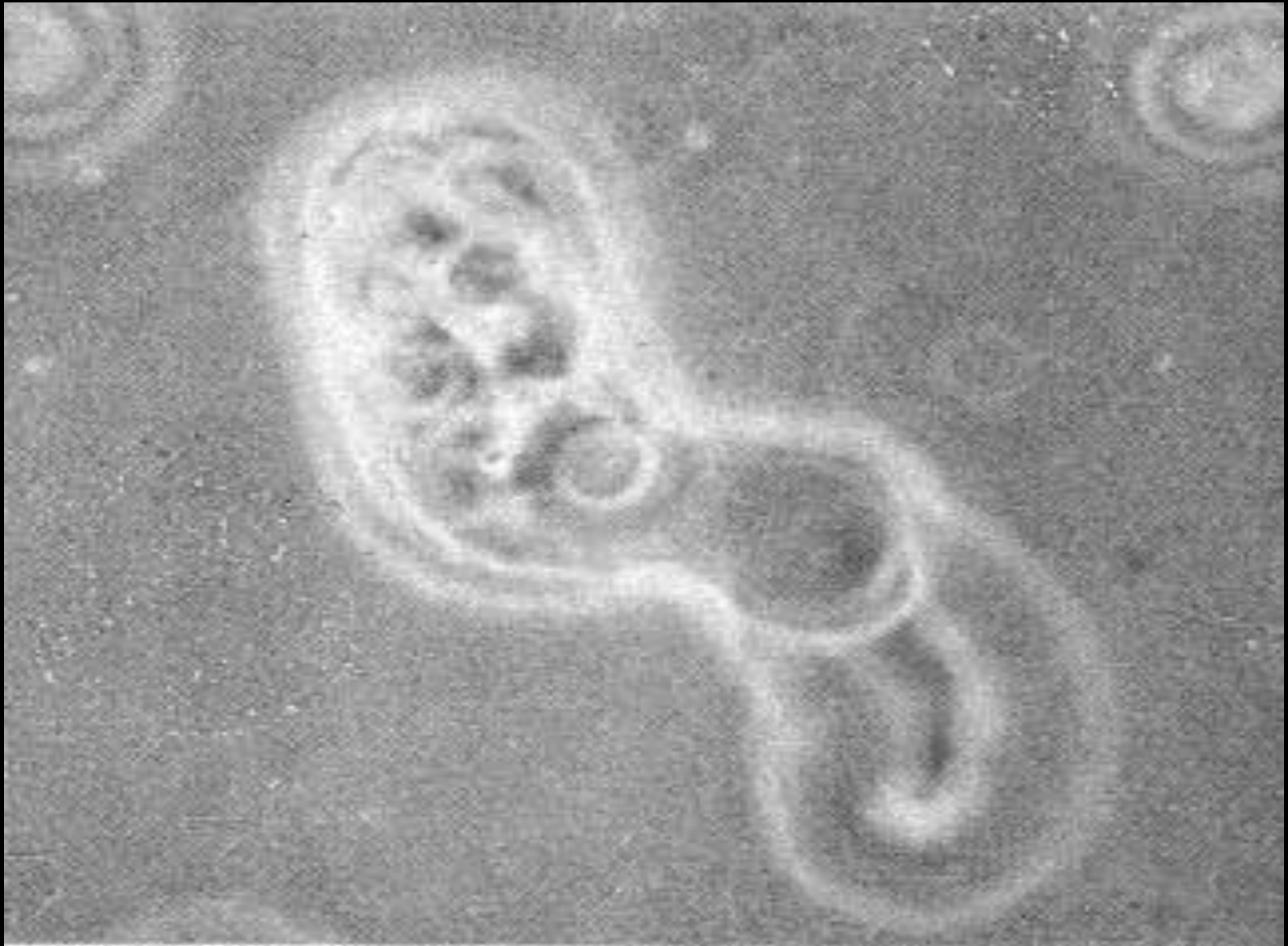Microbiology

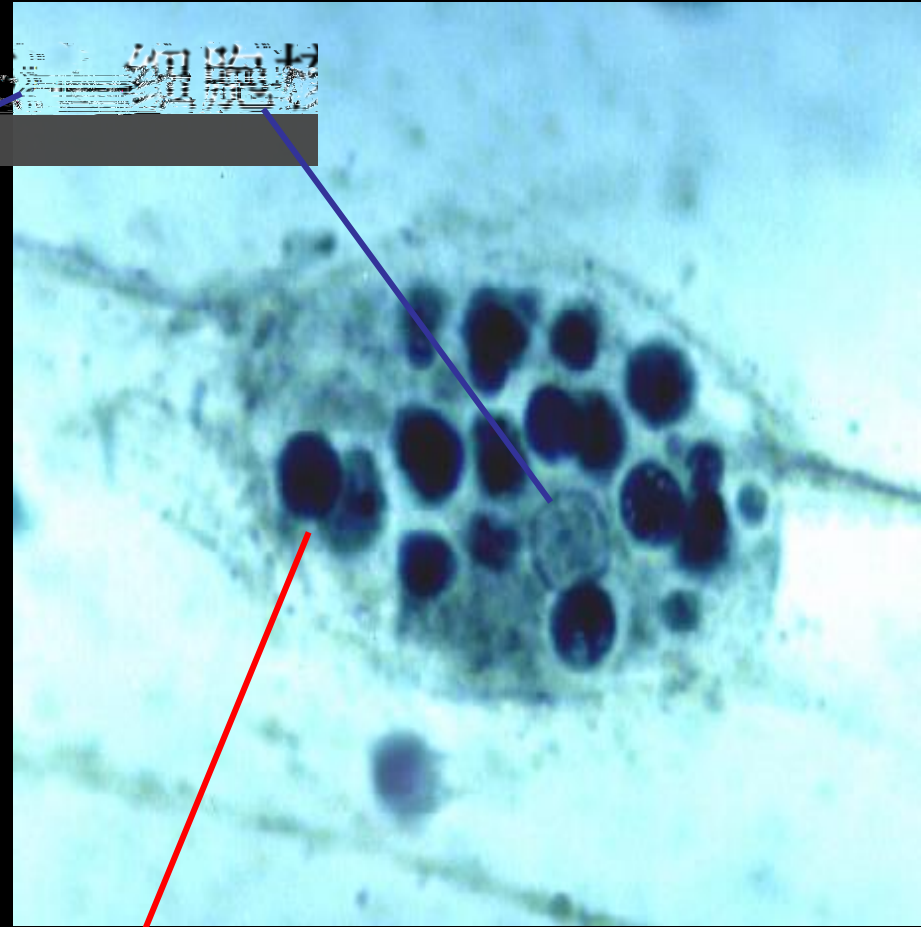
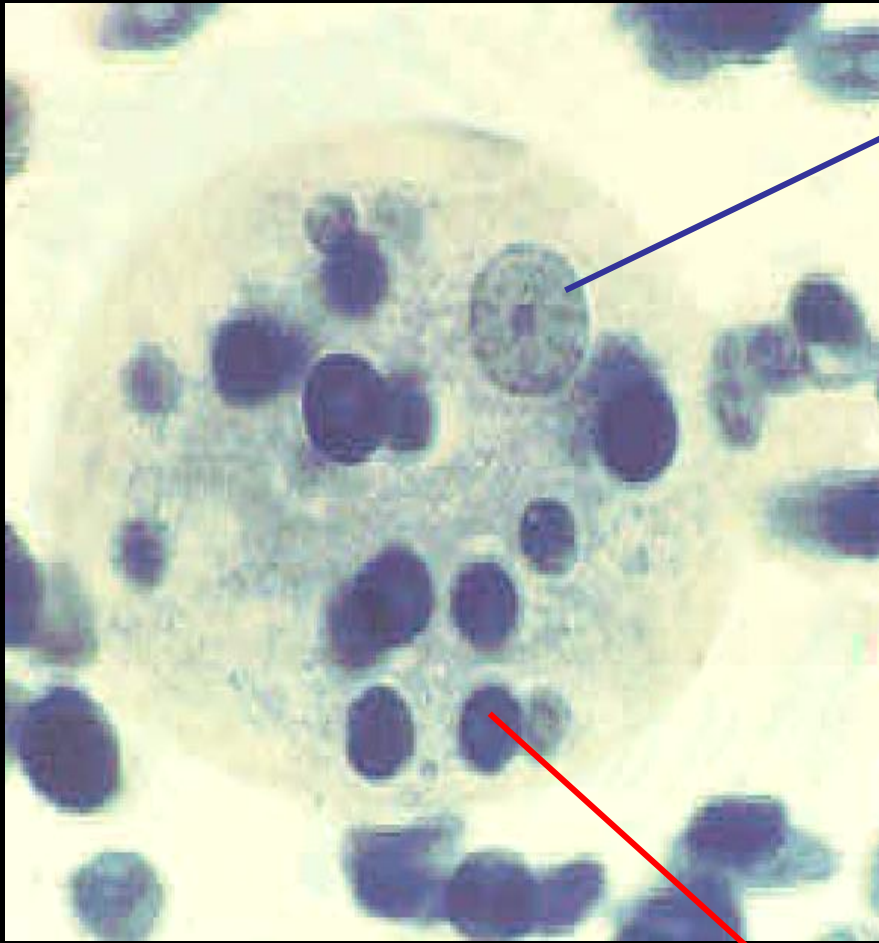
1.

2.

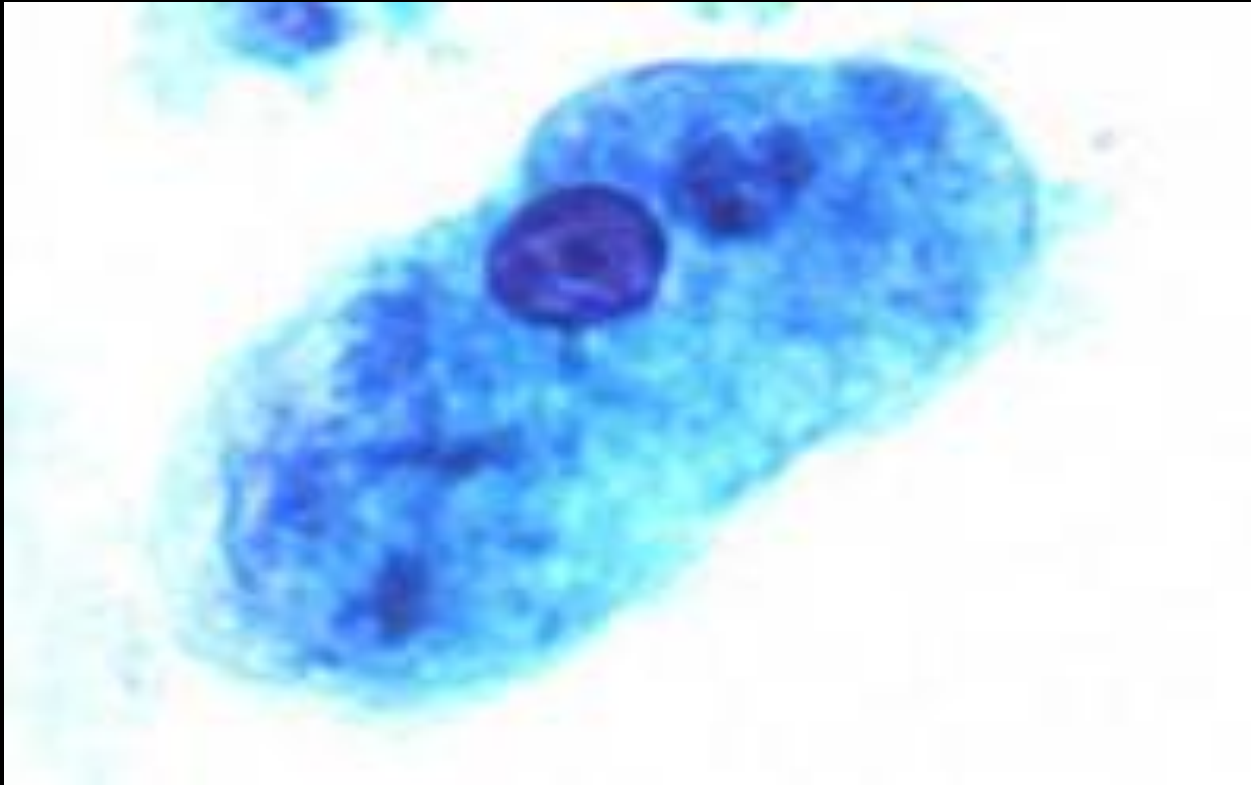


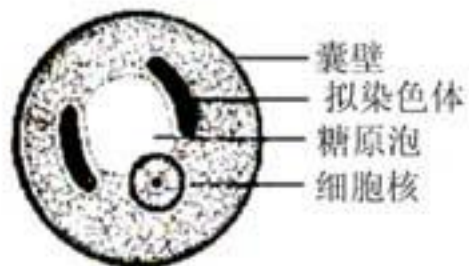




红细胞

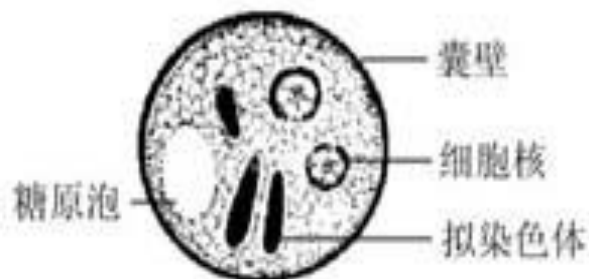
组织内游美体





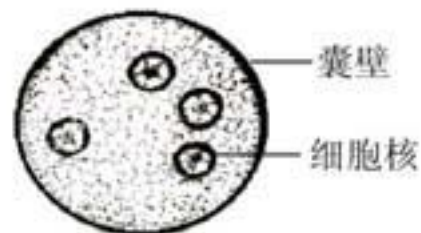
囊壁
拟染色体
糖原泡
细胞核

溶组织内阿米巴包囊
Entamoeba histolytica cyst



囊壁
糖原泡
细胞核
拟染色体

溶组织内阿米巴包囊
Entamoeba histolytica cyst

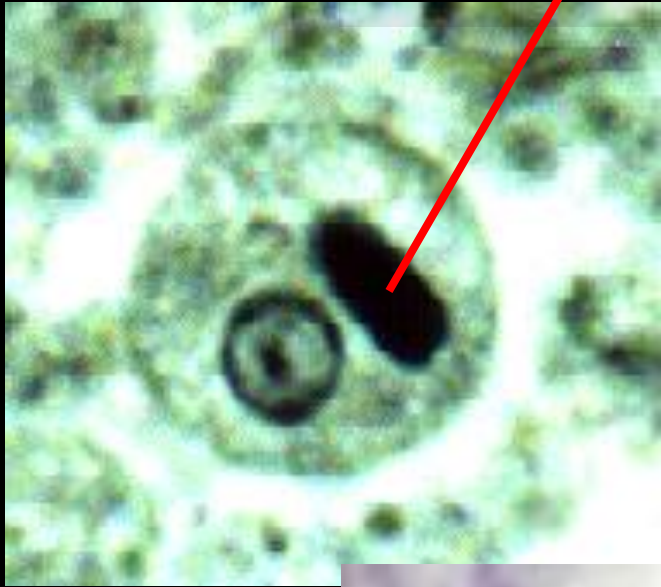

囊壁
细胞核

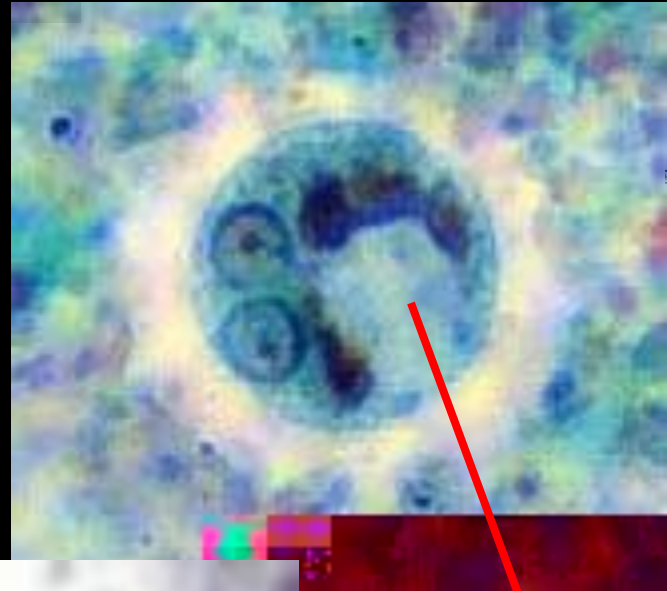
溶组织内阿米巴包囊（四核）
Entamoeba histolytica cyst

抑虫色体

单核包囊



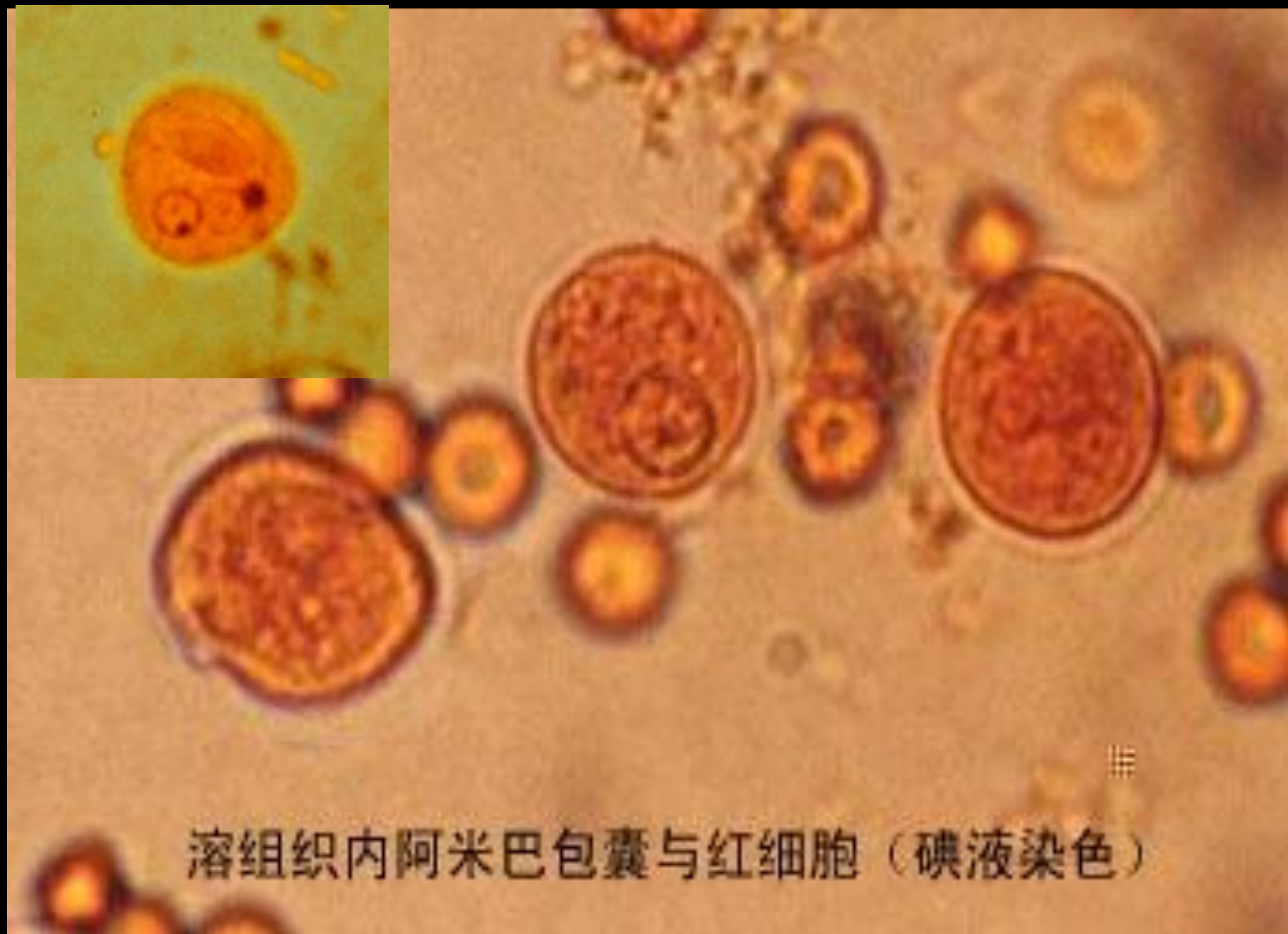
双核包囊



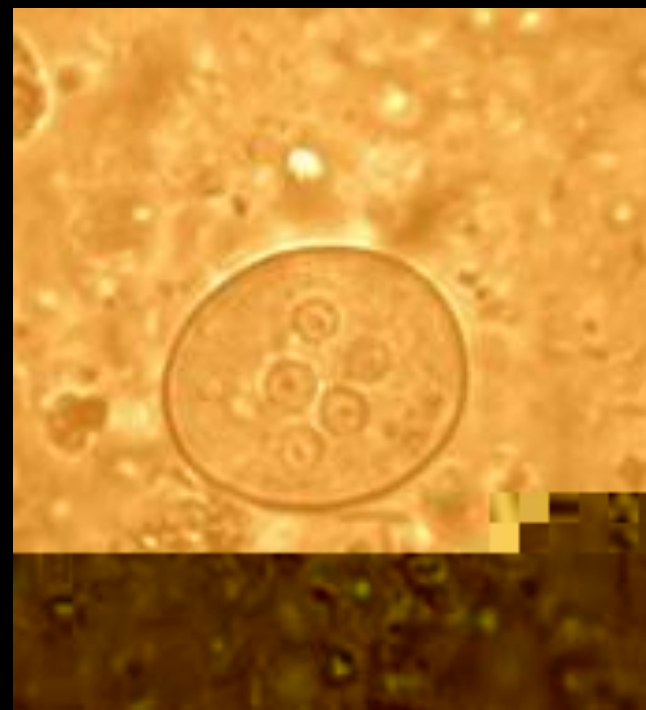
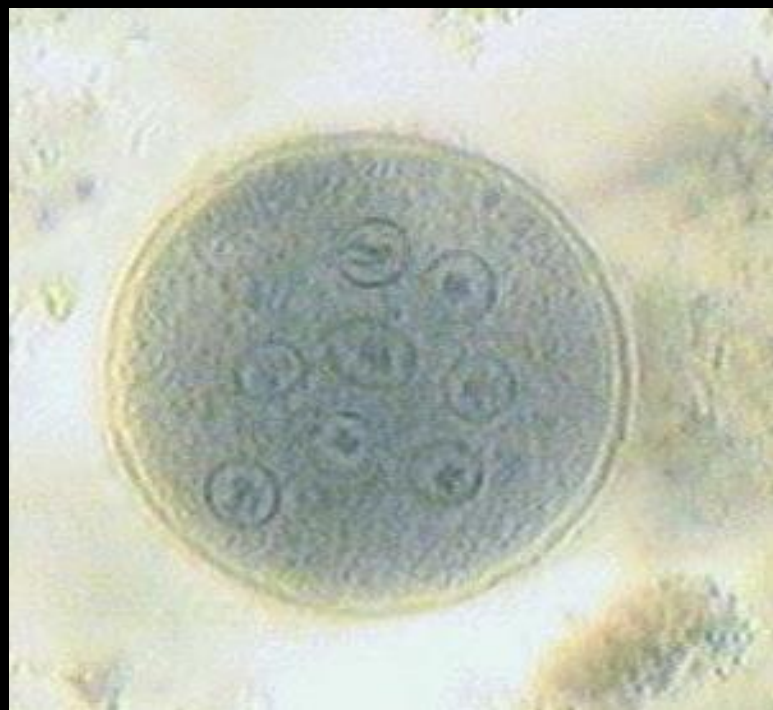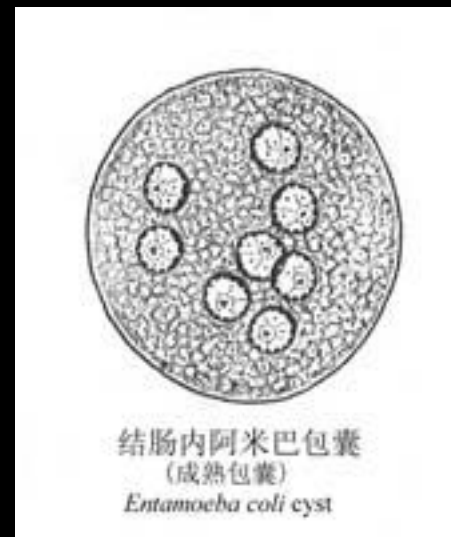
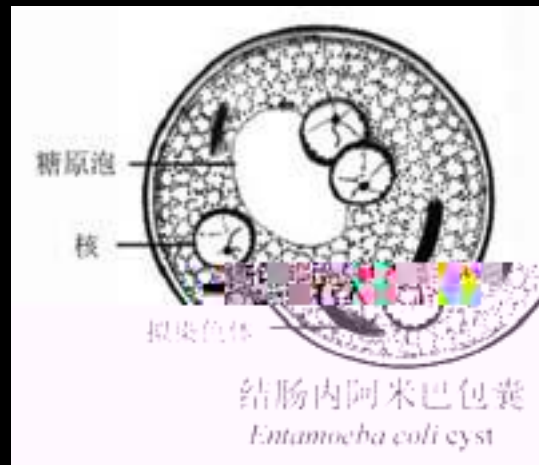

糖原泡

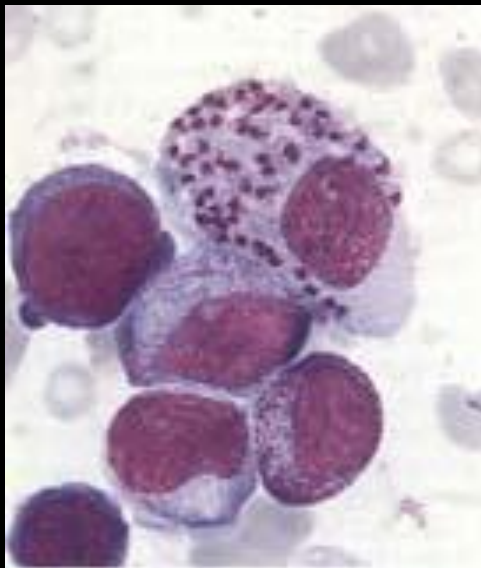
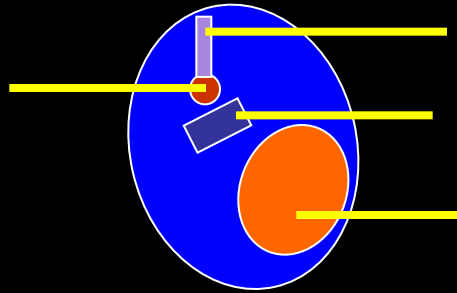
成熟包囊




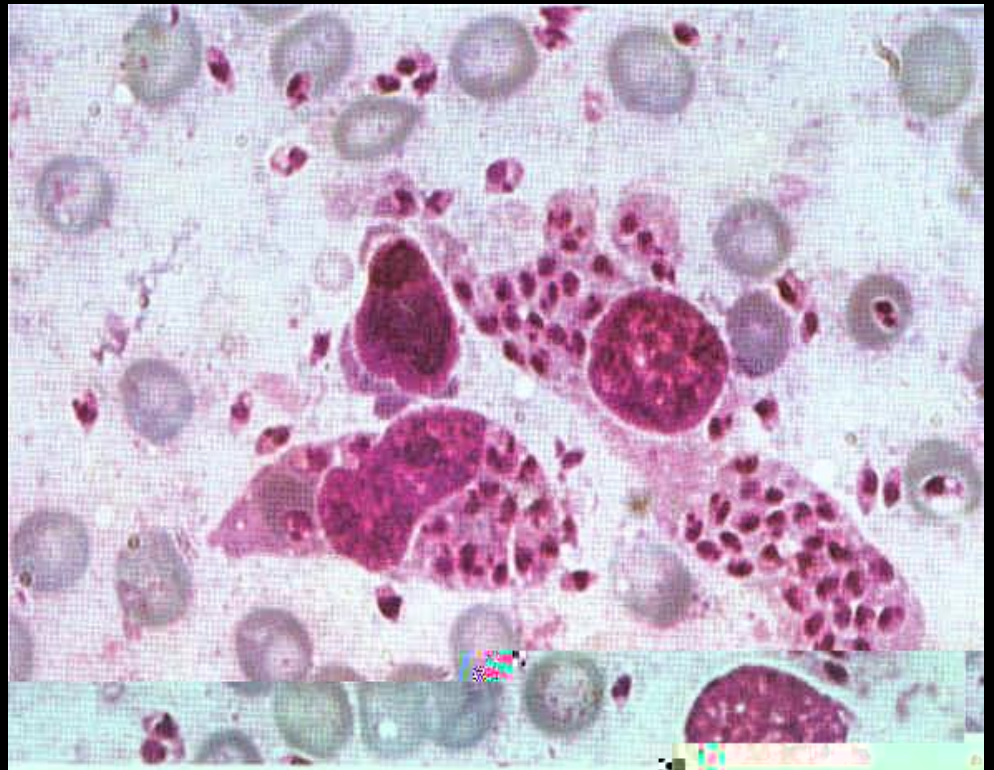


溶组织内阿米巴包囊与红细胞（碘液染色）

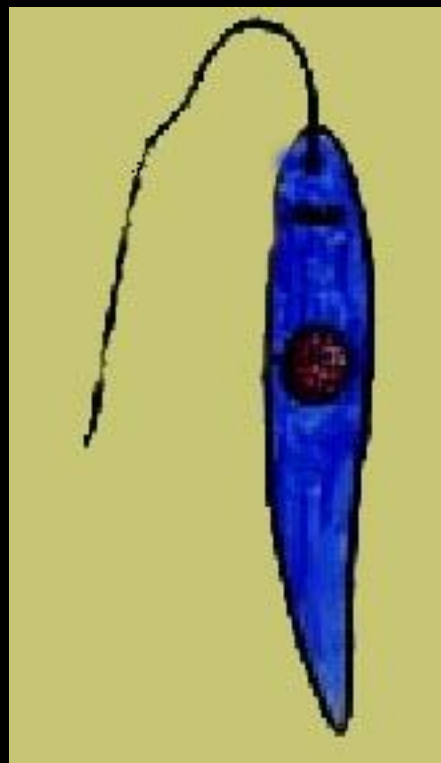



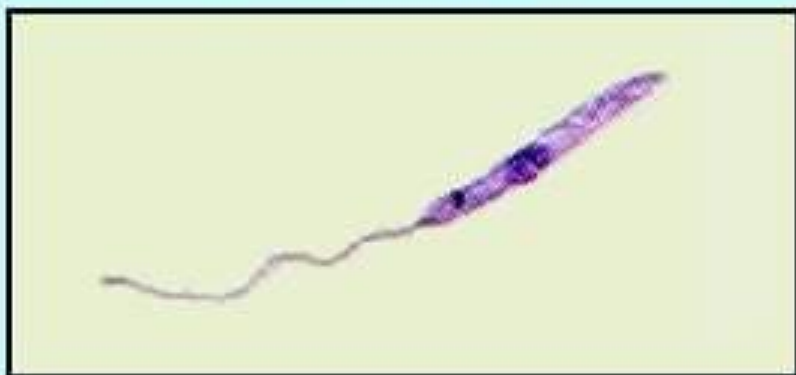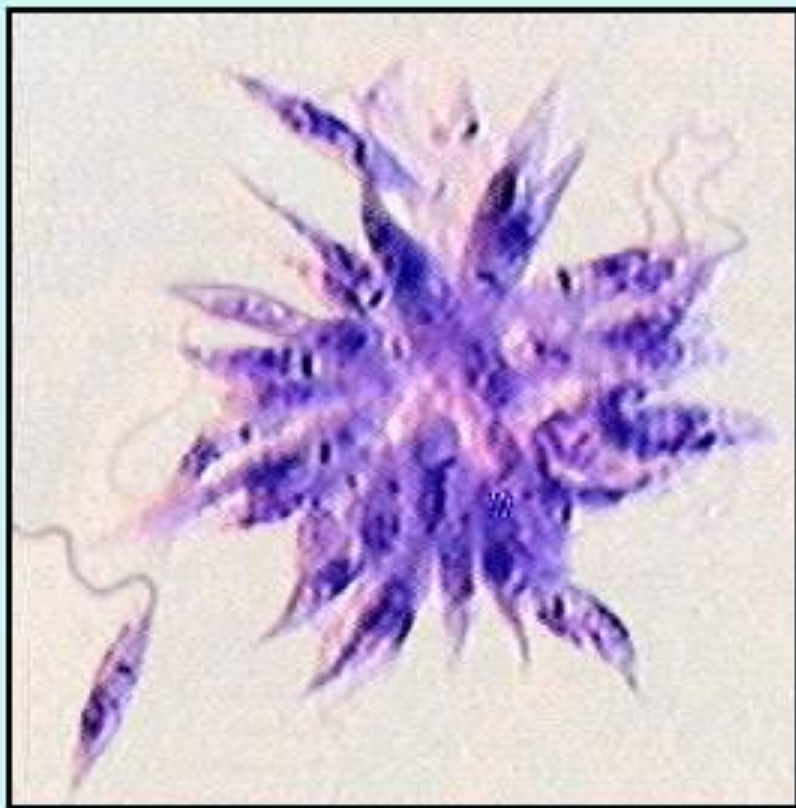
无鞭毛体在骨髓巨噬细胞内
Amastigote in macrophage
from bone marrow

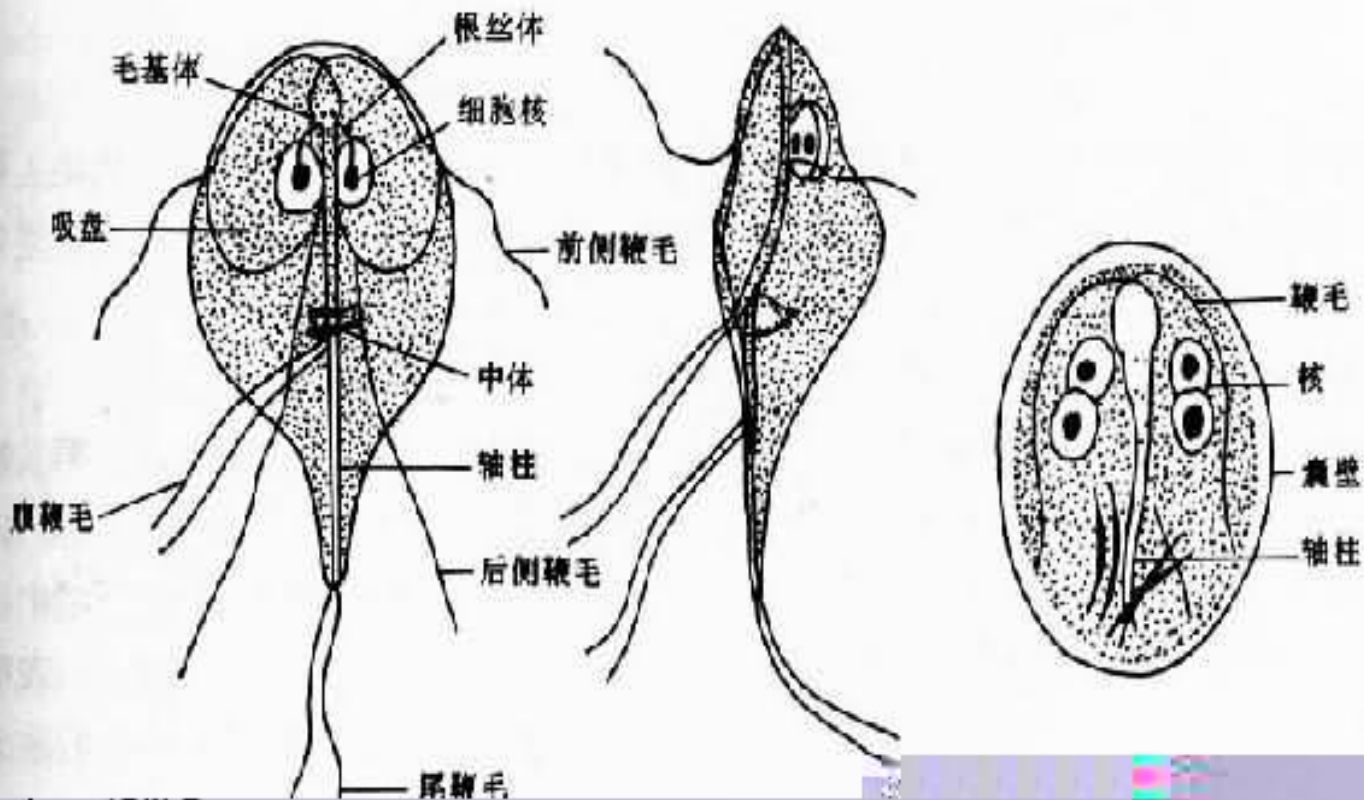


杜氏利什曼原虫



前鞭毛体





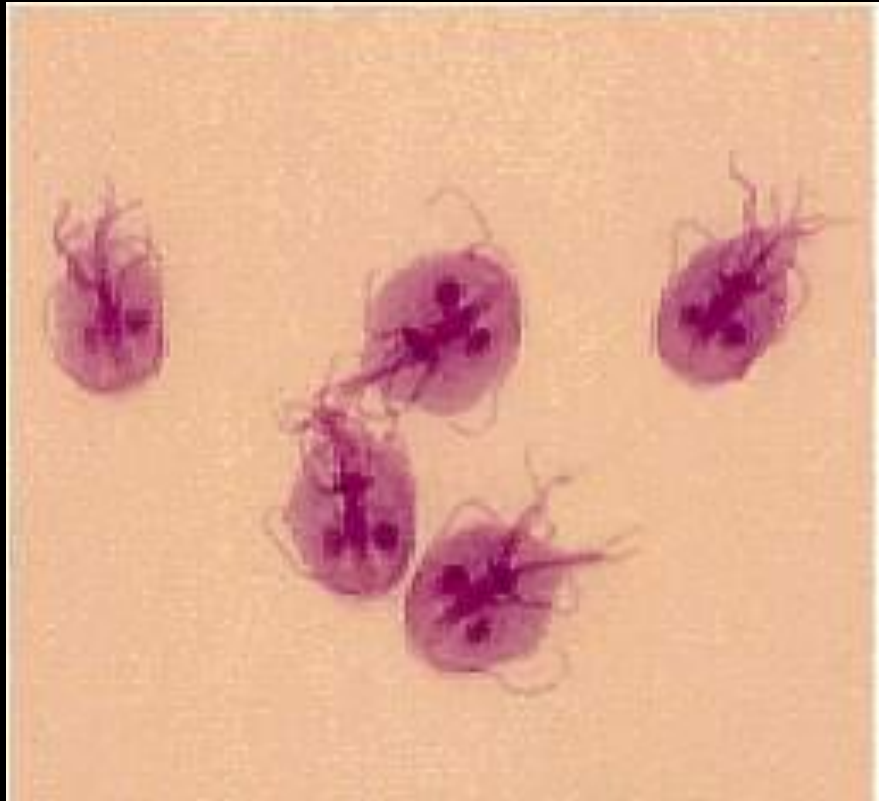
腹面

侧面

成熟包囊


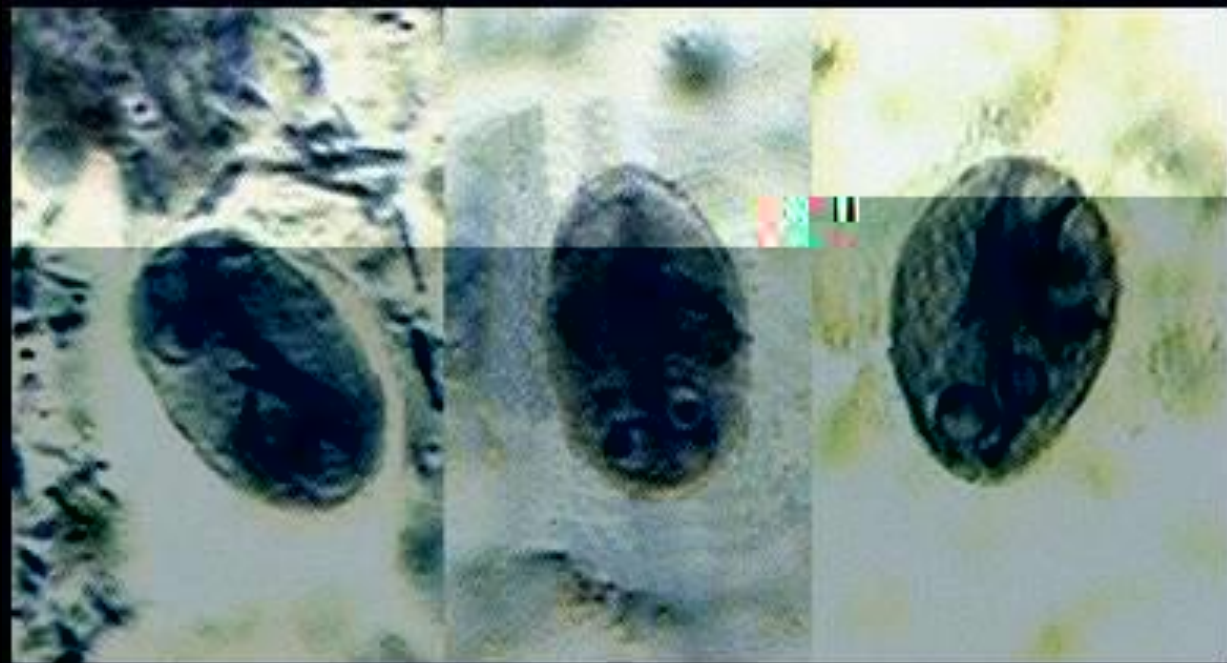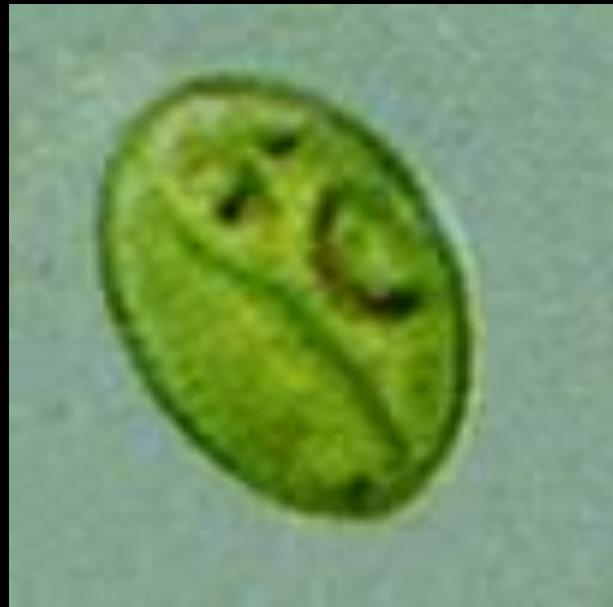
滋养体

蓝氏贾第鞭毛虫



培养物中可见滋养体

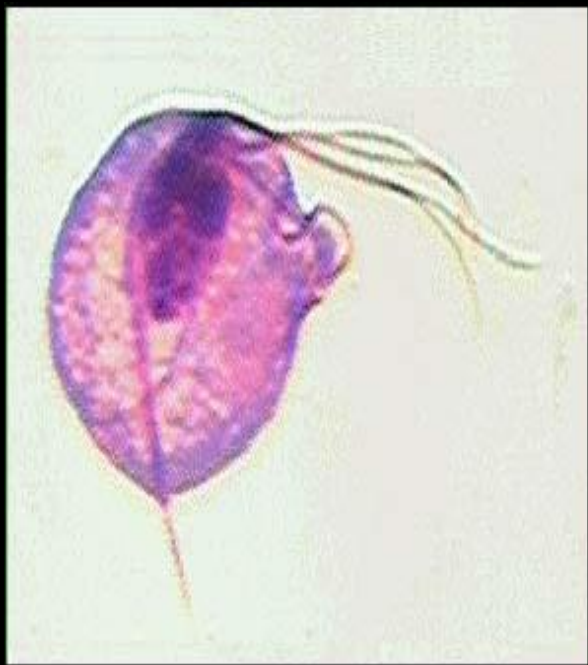
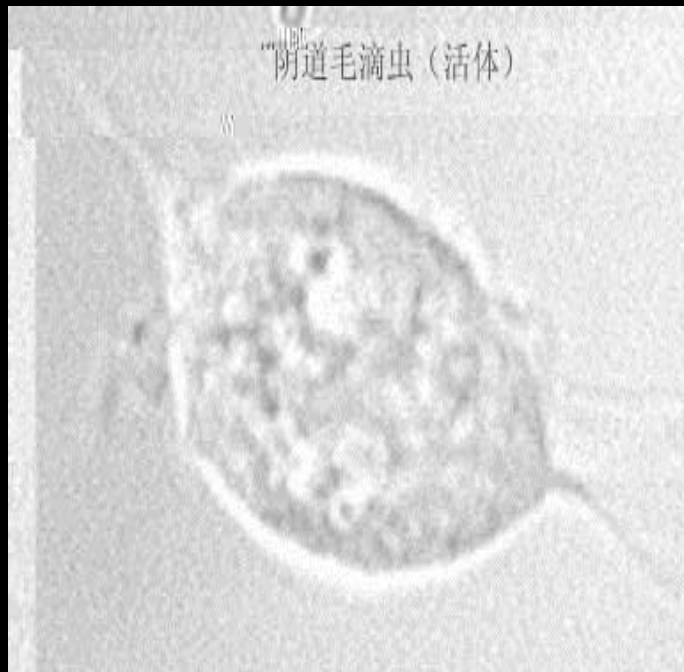
碘液染色滋养体




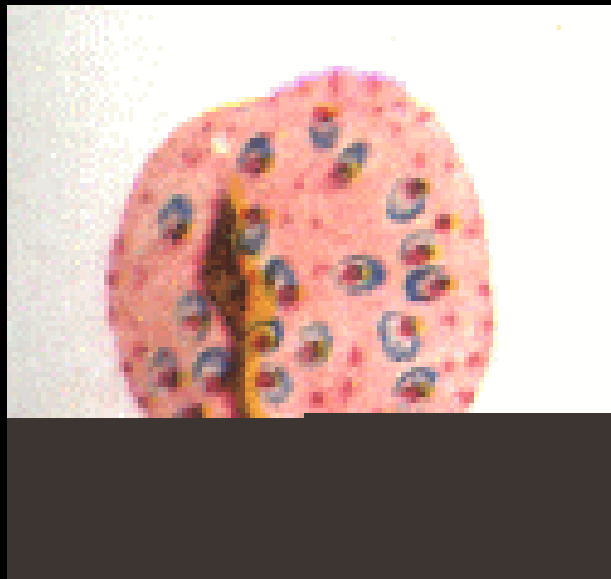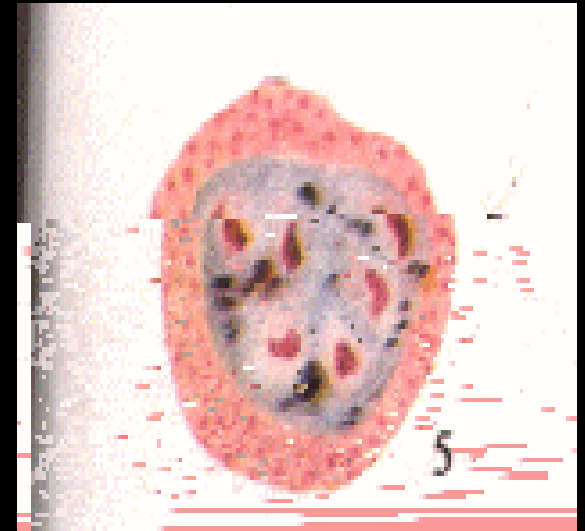
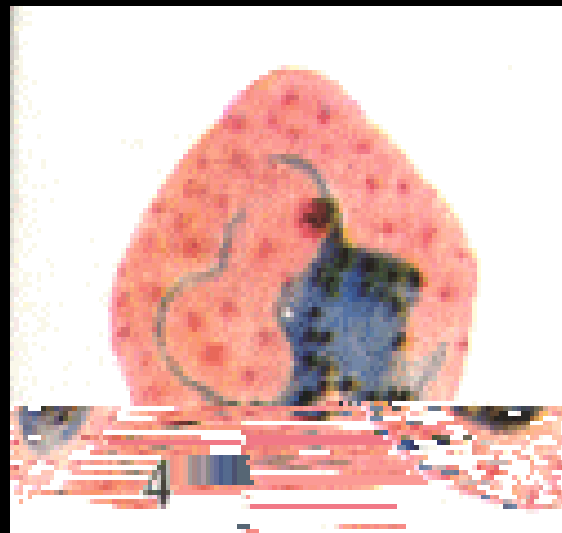
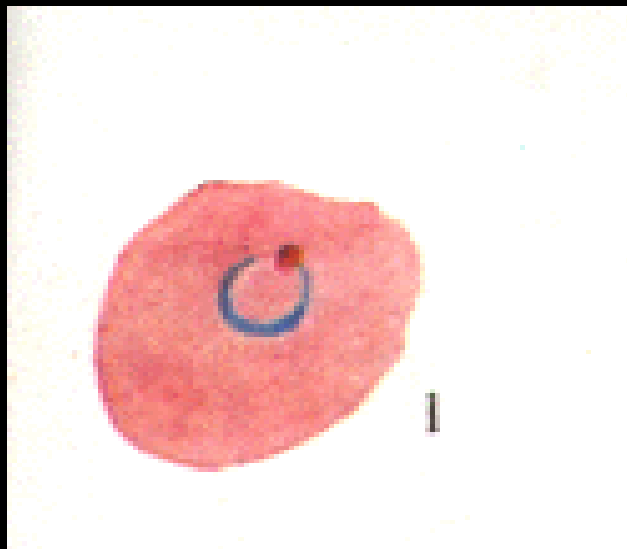
包囊 [cyst]

铁苏木素染色 [iron hematoxylin stain]

阴道毛滴虫（活体）



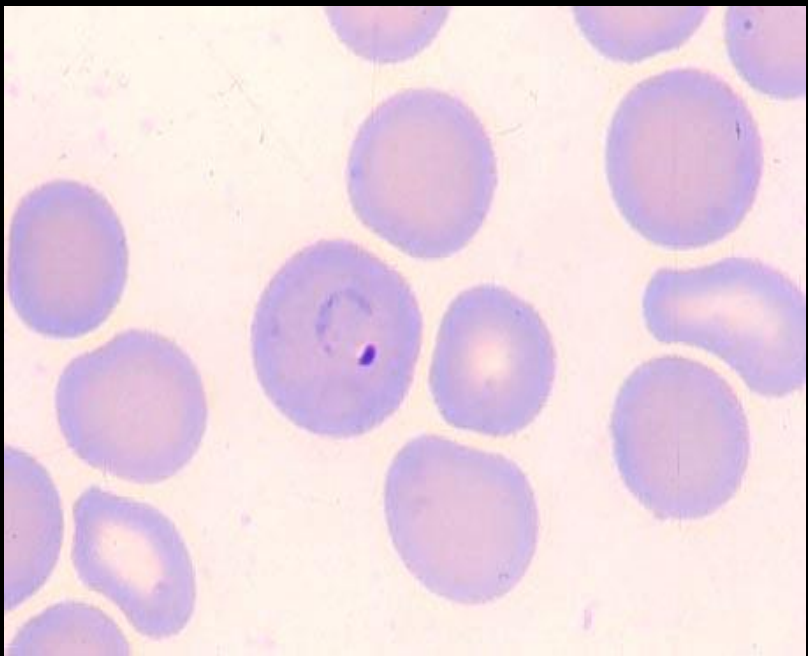
阴道毛滴虫



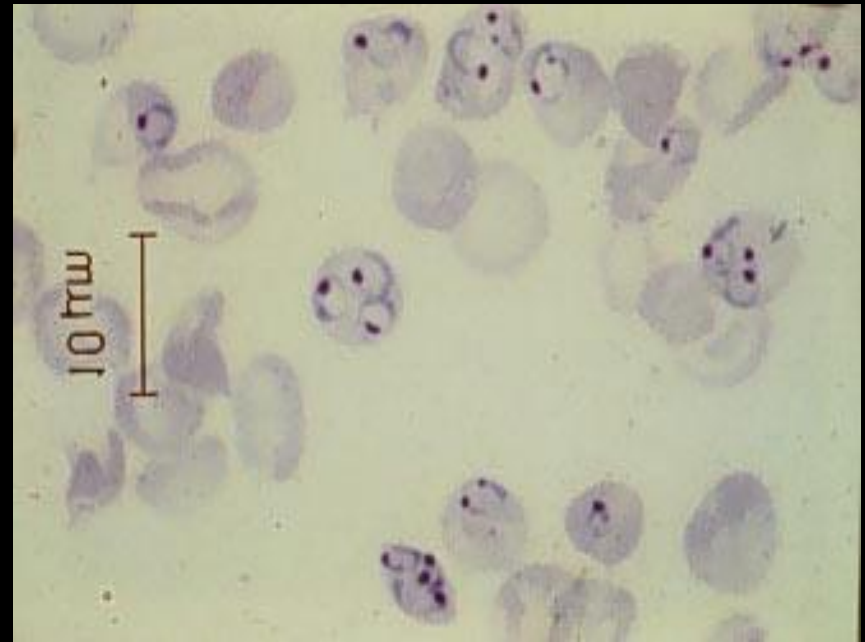
疟原虫

非洲錐蟲與美洲錐蟲在血液中的顯微鏡下形態

Pv

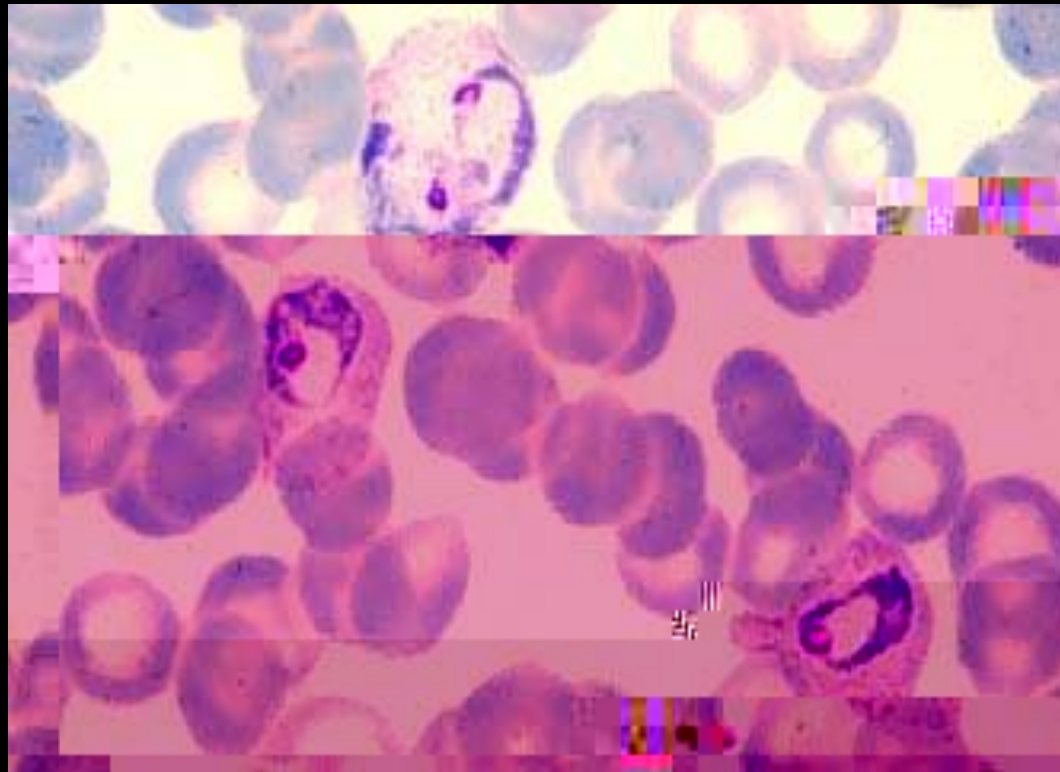


Pf



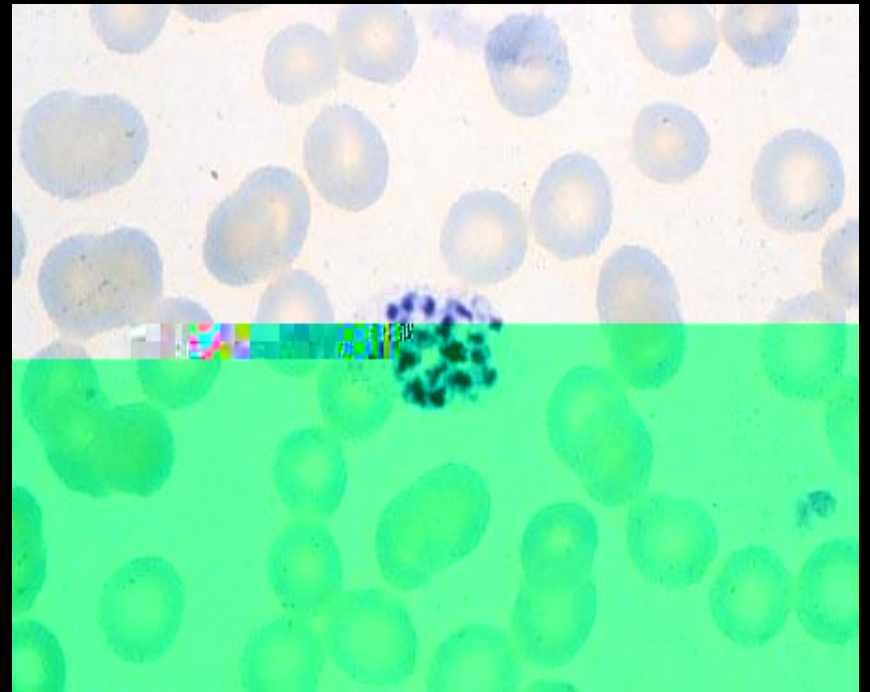
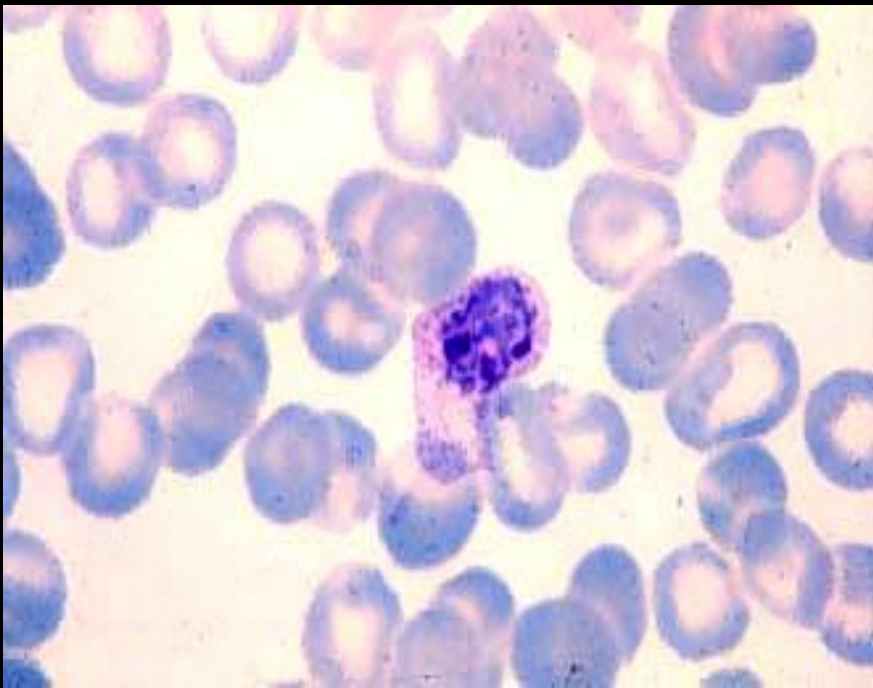
2.

Pv



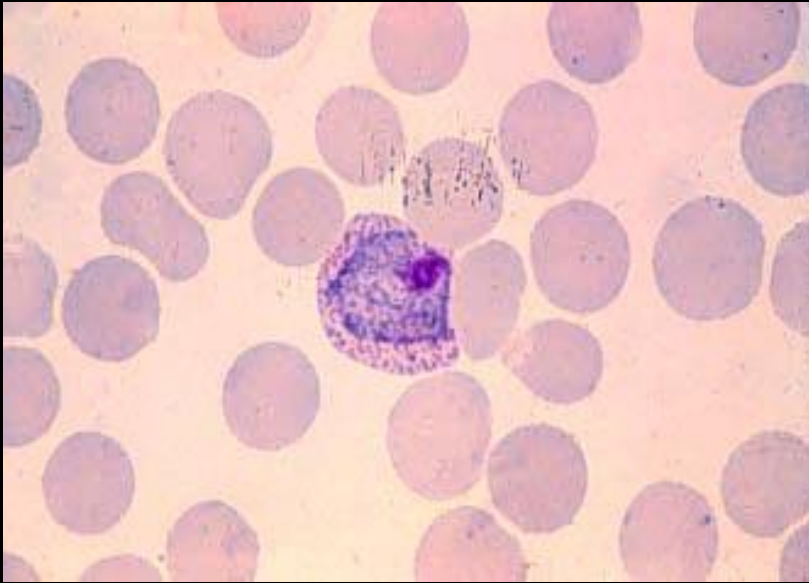
3.

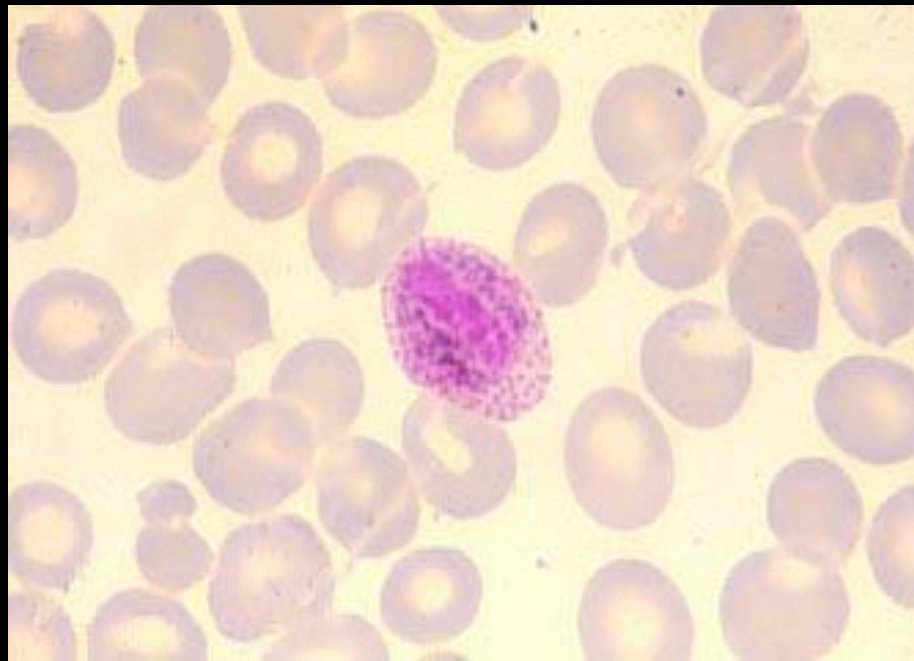
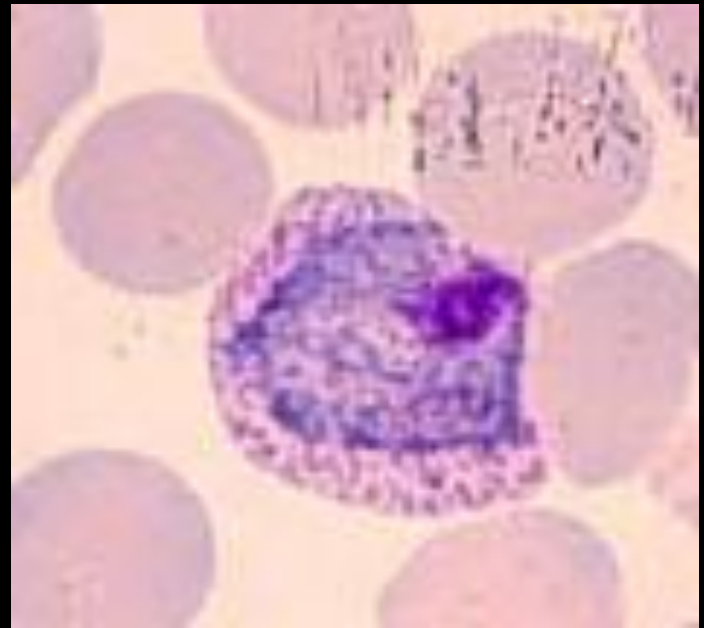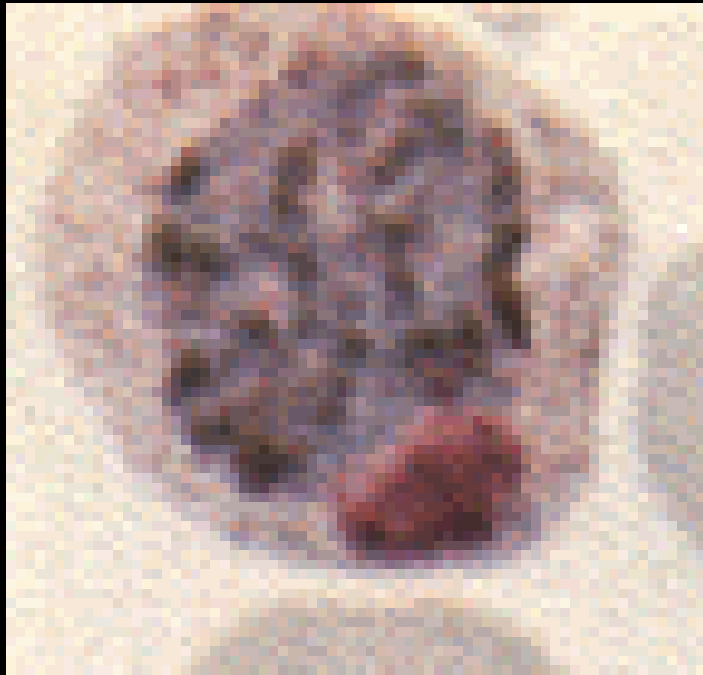
Pv

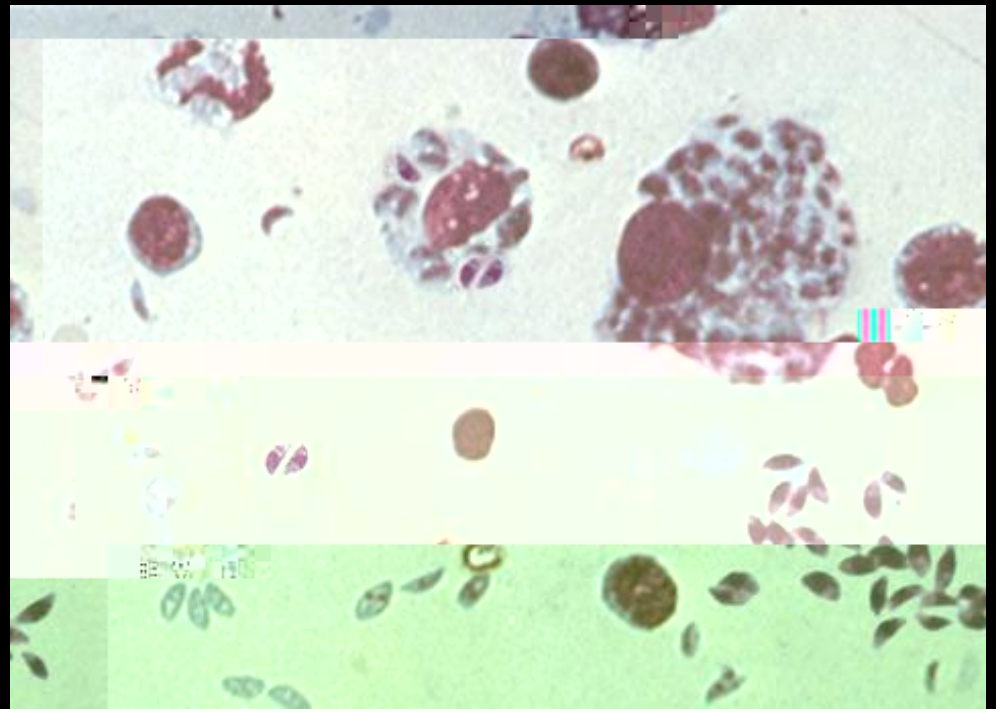
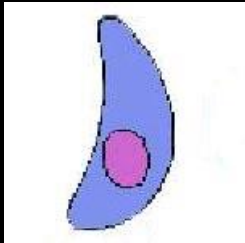
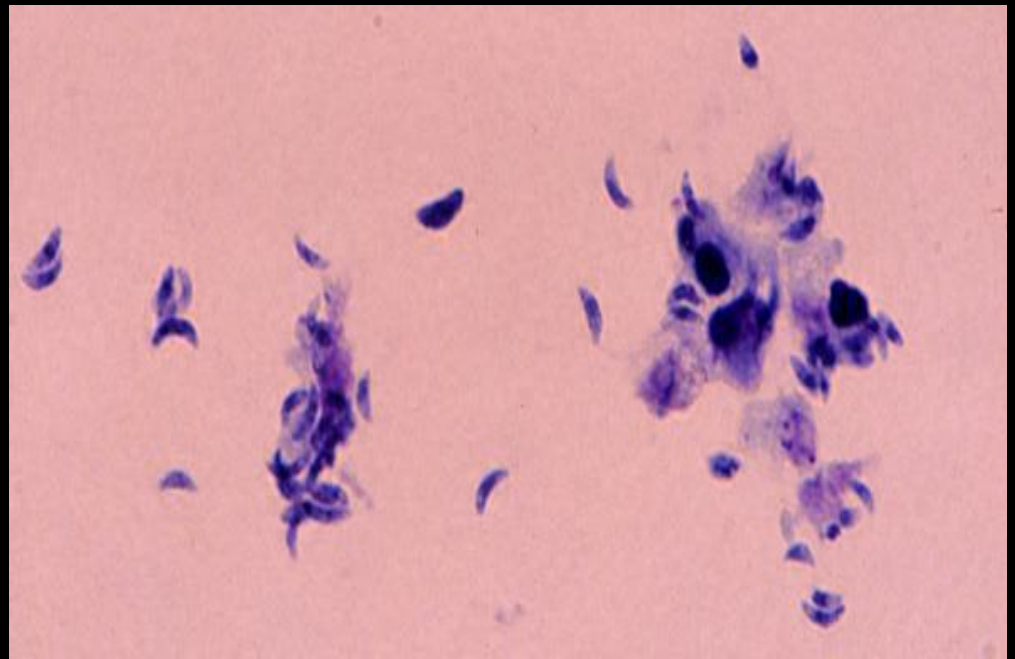
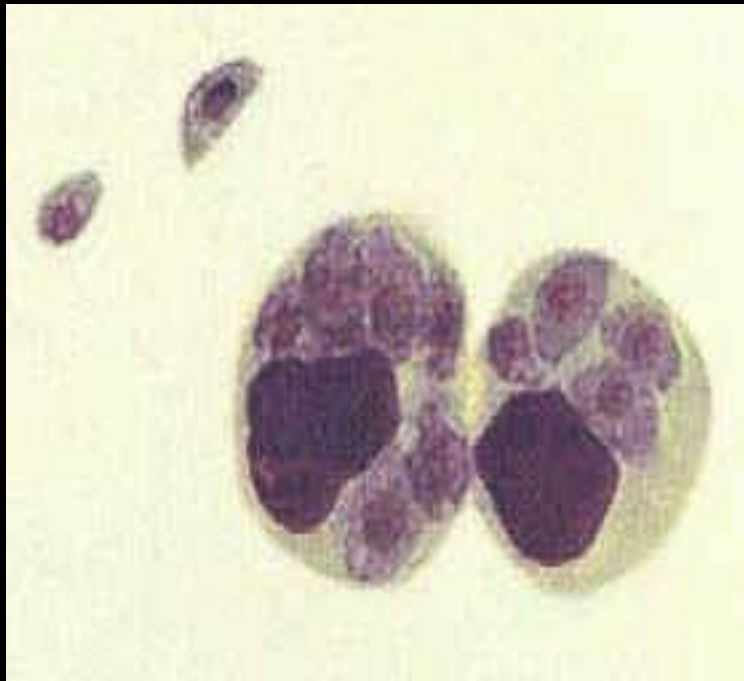

4.

Pv







1.

P.V

2.